

REVASCULARIZATION OF THE LUNATE BY A VOLAR VASCULARIZED BONE GRAFT AND AN OSTEOTOMY OF THE RADIUS IN TREATMENT OF THE KIENBÖCK'S DISEASE

CHRISTOPHE MATHOULIN, M.D.^{1*} and ABHIJEET L. WAHEGAONKAR, M.D.^{1,2}

Kienböck, a German radiologist, described avascular necrosis of the lunate (Kienböck's disease) in 1910. The epidemiology and etiology are not well-known and always has been debated. A negative ulnar variance is considered as a predisposing factor for Kienböck's disease by the majority of the authors. The treatment depends upon the stage of the disease at the time of presentation and diagnosis. Radial shortening and lengthening of the ulna are biomechanically satisfactory procedures because they increase the load sharing of the ulna and result in decompression of the lunate. Revascularization of the lunate by shortening of the radius may appear to be a very bold and ambitious technique. In very advanced cases, palliative procedures like wrist denervation, resection of the proximal carpal row, or wrist arthrodesis are the techniques resorted to. We report our experience of a series of 22 operated cases between 1994 and 2000 with a minimum follow up of 5 years. All cases were treated with an anterior vascularized bone graft based on the volar carpal artery associated to an osteotomy of the radius. © 2009 Wiley-Liss, Inc. *Microsurgery* 29:373–378, 2009.

In 1910, Robert Kienböck described the entity of avascular necrosis of the lunate. He described its typical natural history with carpal collapse leading to secondary arthritis. He thought that ligament injuries and injuries to the vessels in them are the cause of structural changes of the lunate. Idiopathic avascular necrosis (Kienböck's disease) is the most commonly seen ischemic lesion of the lunate. The most evident predisposing factor is the precarious blood supply to the lunate. Negative ulnar variance is considered by a majority of the authors as the most important predisposing factor in Kienböck's disease.^{1–7} Nevertheless, the transmission of the force depends on the variations in the length of the ulna, the thickness of the triangular fibro cartilage complex, the dorsal inclination of the lower end of the radius, and the geometry of the lunate fossa. In fact, it appears that the pathogenesis of Kienböck's disease is multifactorial and is influenced with genetic, anatomic, mechanical, and metabolic factors.

Avascular necrosis can also be post-traumatic following an isolated fracture of the lunate, a perilunate dislocation, and increased intraosseous pressure due to a fracture, an intraosseous cyst, or an osteochondritis dissecans. The symptoms are those of wrist pain, frequently chronic; without any history of trauma. Standard radiographs and tomodensitometry are useful but T1 and T2 weighted MRI images are indispensable to confirm the diagnosis. Wrist arthroscopy can also be an important means for establishing the diagnosis and for verification of the

quality of the cartilage and the status of the scapholunate ligament before definitive surgical treatment.

The treatment depends on the stage of the disease. We follow Buchler's classification,¹ which takes into account the morphology of the lunate and other associated lesions found on paraclinical examination. Stage I: decreased vascularity on MRI, normal structure and form on tomodensitometry, carpal architecture intact on standard radiographs, and no arthritis seen with arthroscopy. Stage II: decreased vascularity on MRI, altered structure and form on tomodensitometry, carpal architecture normal on standard radiographs, no arthritis seen with arthroscopy. Stage III (early): decreased vascularity on MRI, altered structure and form on tomodensitometry, beginning of carpal collapse, no arthritis seen with arthroscopy. Stage III (late): decreased vascularity on MRI, altered structure and form on tomodensitometry, carpal collapse, arthritis seen on arthroscopy but arthritis not apparent radiologically. Stage IV: decreased vascularity on MRI, altered structure and form on tomodensitometry, advanced carpal collapse, arthritis seen on standard radiographs.

If left untreated, Kienböck's disease progresses from stage I to stage IV over several years, which is its natural history. Each stage is not necessarily painful and may be the first presentation of necrosis of the lunate. The purpose of this study is to analyze if the use of vascularized bone graft, associated to a radius osteotomy, allows the revascularization of lunate in case of Kienböck's disease, avoiding the complete destruction of the bone with arthritis.

PATIENTS AND METHODS

Anatomical Basis

We have resorted to the work of Kuhlman et al.,⁸ to describe a graft harvested from the volar aspect of the radius based on the transverse volar carpal artery whose

¹Institut de la main, 6 Square Jouvenet, 75016 Paris, France

²Sanchei Institute for Orthopedics and Rehabilitation, Pune, India

*Correspondence to: Christophe Mathoulin, M.D., Institut de la main, 6 Square Jouvenet, 75016 Paris, France. E-mail: cmathoulin@orange.fr

Received 20 February 2009; Accepted 20 February 2009

Published online 15 June 2009 in Wiley InterScience (www.interscience.wiley.com). DOI 10.1002/micr.20657

pedicle is long enough to allow placement of the graft into the scaphoid or the lunate without any tension (Fig. 1).⁹

The graft is perfused by an anastomosis of arteries located on the distal aspect of the radius and ulna. In 30 cadaver dissections, we have been able to show a constant existence of a transverse volar carpal artery, which was also confirmed in the work of Kuhlman. This vessel arises from the radial artery at the level of the radial styloid process and then crosses the volar aspect of the radius. This artery follows the distal edge of the pronator quadratus and then goes on to anastomose with the distal branch of the anterior interosseus artery and a branch of the ulnar artery over the volar aspect of the distal radioulnar joint, forming a 'T' shaped anastomosis at this level. After branching from the radial artery, the transverse volar carpal artery travels along the lateral third of the distal radius, and then penetrates the radius at the radial epiphysis which assures a good perfusion of the bone.

Technique

Preparation and positioning. The patients are operated in the supine position with a pneumatic arm tourniquet, with the forearm in supination and the extremity placed over a side table. Regional anesthesia is used which allows for day care surgery. A single approach is used for the treatment of Kienböck's disease and for harvesting the bone graft. Wrist arthroscopy can be done when there is a doubt regarding the integrity of the cartilage. It is always desirable to find an intact cartilage with an intact scapho-lunate ligament when the radiographs are less contributory.

Approach. A volar longitudinal incision corresponding to the distal part of Henry's approach is utilized. This approach can be extended with a medial step-cut allowing for extending the incision by opening the carpal tunnel. The radial artery and the tendon of the flexor carpi radialis are identified. After incising the superficial fascia, the wrist is flexed to relax the flexor tendons. The radial artery is carefully retracted laterally and the flexor carpi radialis along with the flexor pollicis longus are retracted medially. One can therefore have a satisfactory exposure of the entire volar aspect of the radius and the carpus.

Identification and dissection of the pedicle. Foucher et al.¹⁰ had shown that the dissection of small arteries can be dangerous. He preferred to harvest a cuff of adjacent tissue along with the artery. This is possible when the artery has a more or less constant course. The transverse volar carpal artery is almost

always located between the periosteum of the radius and the distal margin of the superficial fascia of the pronator quadratus. The dissection of the graft begins with an incision of the fascia and the distal 1-cm of the pronator quadratus allowing a proper exposure of the distal aspect of the radius. The periosteum is incised along the distal and proximal margins of a 1-cm strip of fascia and muscle. The radial half of the strip is elevated with its periosteum off the volar cortex of the radius, by using a combination of a scalpel and an osteotome. The dissection is carried out subperiosteally and on the lateral aspect of the pedicle, up to the radial artery.

Harvesting the graft. The dimensions of the graft are marked on the radius and the graft is harvested using 10 mm osteotomes. The osteotome is placed obliquely on the distal and proximal part of the graft to create a pyramidal shaped graft (Fig. 2). The pedicle and the bone are elevated using 5 mm osteotomes to avoid the risk of damaging the bone graft (Fig. 3).

Dissection of the pedicle. The graft and its pedicle are then dissected to the origin of the transverse volar carpal artery. The most lateral attachment of the pronator quadratus fascia can be divided without hesitation to create a pedicle of about 4–5 cm length (Fig. 4).

Osteotomy of the radius. A shortening osteotomy or a lateral opening osteotomy of the radius is performed routinely. The flexor carpi radialis is retracted medially and the radial artery is retracted and protected laterally. The flexor tendons and the tendon of the flexor pollicis longus are retracted to expose the anterior aspect of the radius, which is covered by the pronator quadratus. The pronator quadratus is elevated off the lateral border of the radius. The muscle is carefully reclined medially and care is taken to avoid injuring the muscle to suture the muscle back at the end of the procedure. The shortening osteotomy of the radius has to be calculated on standard preoperative radiographs in neutral position. Radial translation of the distal radial epiphysis has to be avoided as this will produce a lengthening effect. The level of the osteotomy is at the junction of the epiphysis and the diaphysis of the radius, just at the anterior curvature of the radius. The osteotomy is performed with an oscillating saw and is fixed with a precontoured plate. The new plates with distal locking screws increase the stability of the fixation significantly.

A lateral wedge osteotomy was proposed by Nakamura et al.⁵ in 1991 for cases with neutral ulnar variance. This comprises of an opening wedge osteotomy of the radial epiphysis to reduce the forces acting on the lunate.

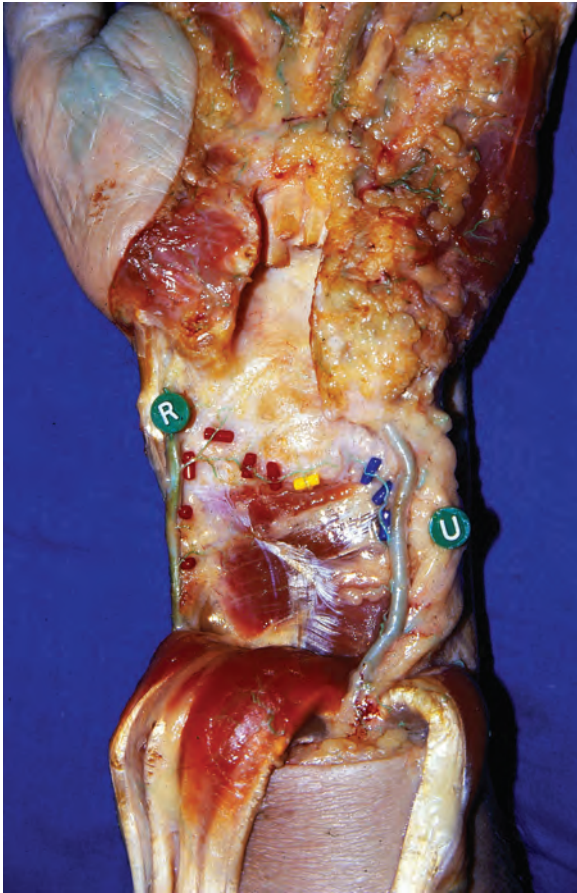

Figure 1. A cadaver specimen showing the transverse volar carpal artery. R = radial artery, U = ulnar artery.

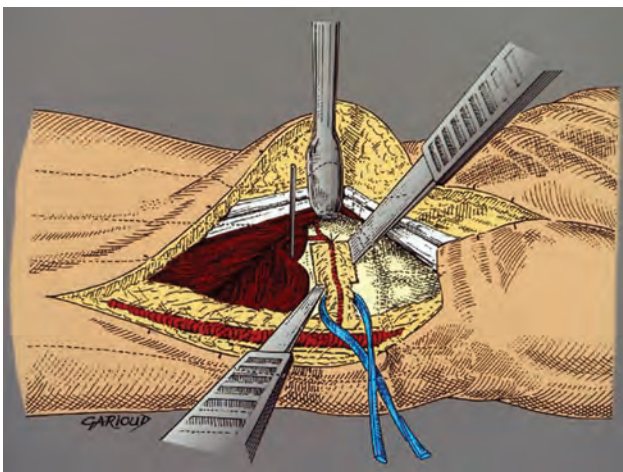


Figure 2. Schematic representation of harvesting of the graft using a narrow osteotome and protecting the periosteal vessels.

A wedge based on the lateral border of the radius, measuring no longer than 3 mm is excised. This osteotomy is then stabilized with a plate. At the end of the procedure, the pronator quadratus is sutured back over the plate to

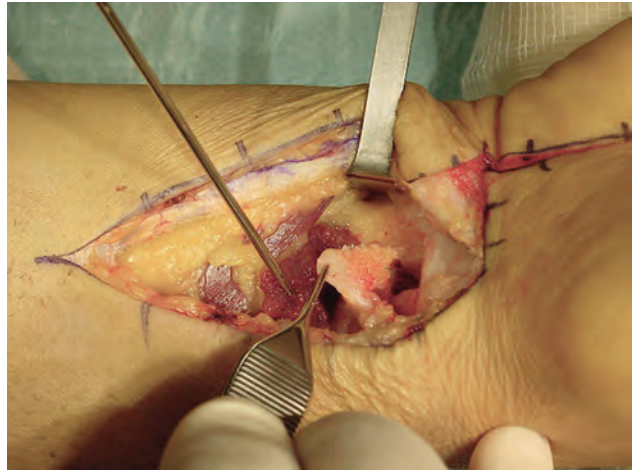


Figure 3. A trapezoidal wedge graft is elevated which is supplied by the transverse volar carpal artery.

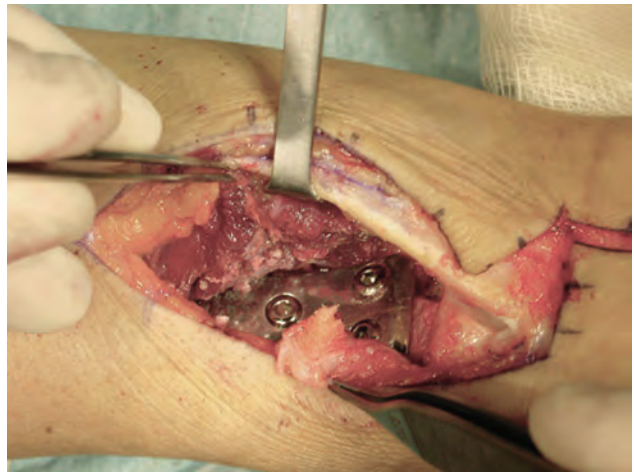

Figure 4. The vascularized bone graft is dissected out till the lateral border of the radius before performing and fixing the osteotomy.

its insertion on the lateral border of the radius using interrupted sutures. This also protects the flexor tendons from rubbing against the plate. After careful hemostasis, the incision is closed in layers over a suction drain. A simple splint is applied until the osteotomy heals (~6 weeks).

Placement of the vascularized bone graft. The capsule of the wrist joint is incised in a 'T' shaped manner. The lunate is exposed and curetted to remove all necrotic bone. The bone graft is then placed to fill the defect in the lunate between the proximal cartilage and the distal end of the lunate. The graft is stabilized with a radio lunate or a scapho-lunate K-wire (Fig. 5).

Closure and postoperative care. The capsule is closed loosely, without compressing the pedicle. The ra-

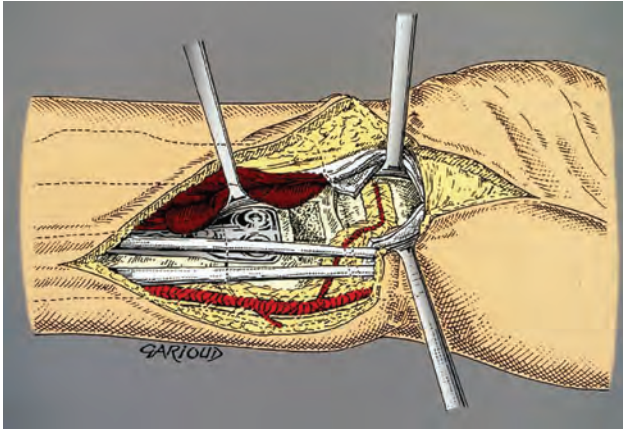


Figure 5. Schematic representation of the vascularized bone graft in place in the lunate after osteotomy of the radius.

dio-scapho-capitate ligament is repaired. The closure is performed over a suction drain. An anterior short arm splint is applied with the wrist in 40° of extension. This functional position is comfortable for the patient and is well permitted by the length of the pedicle. If a pin has been used to stabilize the graft, it is removed at 3 weeks. The anterior radial plate is removed only in case of a problem and never before 1 year has passed.

Patients

We have treated 22 cases of Kienböck's disease between 1994 and 2000. There were eight females and 14 males. The average age was 31.4 years (range, 18–63 years). All patients had a preoperative MRI. According to Buchler's classification,¹ we had eight stage II cases; 10 stage III cases, and four late stage III cases. All patients presented with nonspecific wrist pain, which was the usual presenting symptom. A screening wrist arthroscopy revealed normal cartilage of the lunate in five cases.

There were 17 cases with a negative ulnar variance, which underwent a shortening osteotomy of the radius. In five cases with a neutral ulnar variance, an opening wedge osteotomy was performed. One patient with stage II disease, who was treated with an opening wedge osteotomy, had a relapse of early stage III with beginning of carpal collapse. A secondary vascularized bone graft was performed, which controlled the condition 6 months after the intervention. The patient was followed up for 9 years, with no further progression of the disease, and had a good pain-free range of motion with good strength comparable to the opposite side and a normal MRI at last follow-up.

RESULTS

The average follow up was of 74 months (range, 60–124 months). Eighteen patients were completely pain free

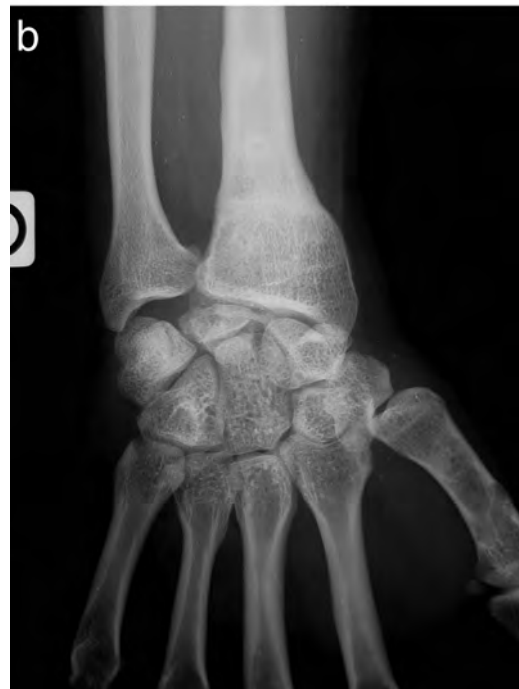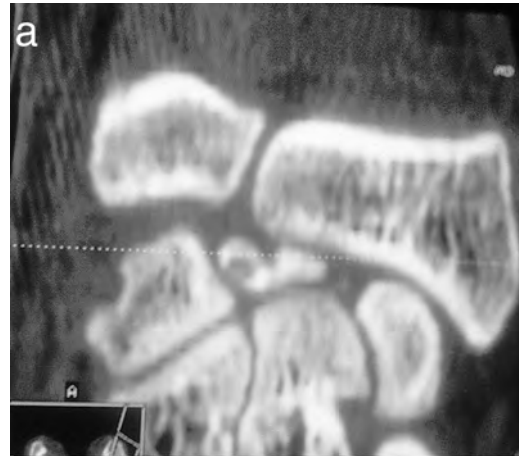


Figure 6. (a) CT scan image of a late stage III case showing complete destruction of the lunate. A preoperative arthroscopy revealed intact lunate cartilage. (b) Postoperative X-ray at 9 years follow-up showing satisfactory revascularization of the lunate with a particular shape of the lunate. The patient was pain-free with only terminal loss of wrist extension.

and the pain subsided in two cases. Pain remained unchanged in two cases which were our failed cases. The range of motion and strength increased significantly in all our cases. All our patients had a preoperative MRI and a postoperative MRI at an average of 8 months after surgery. Certain patients had 2 or 3 MRI examinations in the follow-up period. The average time to return to normal activities was 3.5 months (range, 1–6 months). The radiological and MRI data revealed that 17 cases were completely treated, three cases were stabilized, and two

Table 1. Statistic Correlation (Bivariate Correlation)

	Statistical correlation	P value
Good functional outcome	Stage II disease	<0.001
	Age < 40 years	0.001
	Sedentary	0.003
	Time from diagnosis to surgery-short	0.005
	Sex	0.22
	Type of osteotomy	0.55

cases which had aggravations required a secondary palliative surgery (Figs. 6a and b). The further progress of Kienböck's disease in the so-called stabilized cases remains mysterious. We had five cases in whom the pain disappeared, but the radiographic images remained unchanged. Three of these cases remained status quo radiologically. Of the other two cases, one was controlled 4 years later with a well-vascularized lunate, implying a questionable role of the graft. The other patient had an aggravation of symptoms after 5 years, and was among our two failures, and required a secondary palliative procedure.

We had four delayed unions of the radius due to a very proximally located osteotomy. There was one case of reflex sympathetic dystrophy, which was rapidly treated and controlled without any sequelae. According to the Mayo Clinic Wrist Score, we had eight excellent results, seven good results, four average results, and two poor results. We have always found a direct correlation between the type of the result achieved and the stage of the disease, the age and the delay between diagnosis, and the treatment (Table 1). There was no correlation between the functional result and the sex of the patient or the type of osteotomy performed.

DISCUSSION

Other than post-traumatic cases, Kienböck's disease remains an entity of unknown origin. The clinical presentation is often that of chronic wrist pain. Standard radiographs, tomodensitometry, and MRI are important to establish a diagnosis of this condition. This allows us to group the patients according to different stages of the disease, which in turn require different types of treatment. Most of the literature on this subject has shown that it is difficult to evaluate the efficacy of the different treatment modalities of Kienböck's disease.

There are various treatment options available, either independently or in combinations. In addition, the number of cases is often less as Kienböck's disease is a rare entity. The different classification systems need not necessarily be adapted to our particular needs. The return to work and activities of daily living are often not well-

analyzed and lastly, the evaluation methods and the results are most often different. The goal is therefore to impart an efficient treatment for stage I disease, and to try and avoid complications and drastic palliative procedures in the advanced stages.

Adjustments in the lengths of the radius and the ulna appear to be the procedures of choice in cases with stage II and stage III disease, and they give the most constant results.

Vascularized bone grafting appears to be the method of choice for the reconstruction of the lunate in Kienböck's disease. The shape of the lower end of the radius is open toward the front with a posterior slope and an oval articular surface which is completely covered by articular cartilage on its dorsal and proximal surface which is favorable for treatment using a volar approach. One can harvest a vascularized bone graft based on the volar transverse carpal artery, which lies on the volar aspect of the radius and perform a shortening osteotomy of the radius at the same time using this approach.

Because of the difficulty associated with this technique, the utilization of a vascularized bone graft was exclusively reserved for failed cases resulting from other standard techniques. In 1965, Roy-Camille¹¹ was the first to suggest the utilization of a vascularized bone graft harvested from the volar aspect of the radius with its blood supply from the fibers of the pronator quadratus. This technique was later used by Braun¹² and more recently by Kawai and Yamamoto.¹³

It seems logical to us to perform curettage of the necrotic bone and a vascularized bone graft in addition to length adjustments, as it has given us very encouraging and satisfactory results.

Nevertheless, there are several biases in this study. An osteotomy alone could have perhaps given the same results. But we have seen in one case that an osteotomy alone could not achieve a revascularization of the lunate and only a vascularized bone graft could resolve this case. On the other hand was the graft alone capable of revascularizing the lunate? This could be possible, but we have arbitrarily chosen to perform an osteotomy along with a vascularized bone graft in each case to diminish the pressure and forces on the carpus. Lastly, is it necessary to operate stage II disease? The answer probably could be found by recalling the case of stage II disease, which progressed in spite of an osteotomy of the radius, and by the fact that all other stage II cases had been definitely resolved by this technique.

The progression of the so-called stabilized cases remains mysterious. We had five cases in whom the pain disappeared, but the radiographic images remained unchanged. Three of these cases remained status quo. Of the other two cases, one was controlled 4 years after-

wards with a well-vascularized lunate, implying a questionable role of the graft. The other patient had an aggravation of symptoms after 5 years, and was among our two failures, and required a secondary palliative procedure.

Three different types of treatment can be thought of: 1) adjustment of length of the forearm bones, 2) revascularization of the lunate, and 3) wrist denervation. The factors that need to be taken into account are the age and the functional demands on the patient. In stage I disease, a simple immobilization during symptomatic periods appears to be sufficient. In stage II disease, adjustment of the length of the forearm bones associated with a revascularization is often proposed. In early stage III, length adjustment along with a vascularized bone graft has become the most logical treatment. In late stage III, depending on the findings of an arthroscopy of the wrist; one may propose a tentative reconstruction by length adjustment and revascularization, or a proximal row carpectomy in elderly patients. In stage IV with generalized arthritis, one may choose between a wrist denervation and a complete wrist arthrodesis.²⁻⁴

In spite of the inevitable bias in this study, due to the arbitrary selection of multiple treatment modalities described in the vast literature on this subject, viz. reduction of the forces and pressure, curettage of the bone, and vascularized bone graft, this method can be proposed as a treatment for Kienböck's disease stage II and onwards, in view of the quality of the results obtained and a follow up period which is sufficiently long to render this analysis reliable. This procedure is convenient for the patient: Harvesting the vascularized bone graft from the volar aspect of the radius through a simple anterior approach and performing an osteotomy at the

same time under regional anesthesia makes this an outpatient ambulatory surgery.

REFERENCES

1. Buchler U. Nécrose avasculaire du semi-lunaire, in enseignement de la chirurgie de la main, expansion scientifique française Paris, 1993
2. Masear VR, Zook EG, Pichora DR, Kricshnamurthy M. Strain-gauge evaluation of lunate unloading procedures. *J Hand Surg Am* 1992; 17:437-443.
3. Trumble T, Glisson R, Seaber A, Urbaniak J. Biomechanical comparison of the methods for treating Kienböck's disease. *J Hand Surg Am* 1986;11:88-93.
4. Verner FW, Palmer AK, Fortino MD, Short WH. Force transmission through the distal ulna: Effect of the ulnar variance, lunate fossa angulation, and radial and palmar tilt of the distal radius. *J Hand Surg Am* 1992;17:423-438.
5. Nakamura R, Tsuge S, Watanabe K, Tsunoda K. Radial wedge osteotomy for disease. *J Bone Joint Surg Am* 1991;73:1391-1396.
6. Personn M. Pathogenese und behandlung der Kienböck schen lunatummalazie. *Acta Chir Scand* 1945; Suppl:1-159.
7. Armistead R, Lischend R, Dobyns J, Beckenbaugh R. Ulnar lengthening in the treatment of Kienböck's disease. *J Bone Joint Surg Am* 1982;64:170-178.
8. Kuhlman JN, Mimoun M, Boabighi A, Baux S. Vascularized bone graft pedicled on the volar carpal artery for nonunion of the scaphoid. *J Hand Surg Br* 1987;12:203-210.
9. Haerle M, Schaller HE, Mathoulin C. Vascular anatomy of the palmar surfaces of the distal radius and ulna: Its relevance to pedicled bone grafts at the distal palmar forearm. *J Hand Surg Br* 2003; 28:131-136.
10. Foucher G, Braun JB, Merle M, Sibilly A. Le lambeau "cerf-volant." *Annales de chirurgie de la main* 1978;32:593-596.
11. Roy-Camille R. Fractures et pseudarthroses du scaphoïde carpien. Utilisation d'un greffon pédiculé. *Actualité en chirurgie orthopédique* 1965;4:197-214.
12. Braun RM. Viable pedicle bone grafting in the wrist. In: Urbaniak JR, editor. *Microsurgery for Major Limb Reconstruction*. St Louis: Mosby; 1987. pp 220-229.
13. Kawai H, Yamamoto K. Pronator quadratus pedicled bone graft for old scaphoid fractures. *J Bone Joint Surg Br* 1988;70:829-831.