

Arthroscopic Bone Grafting for Chapter 19 Scaphoid Nonunion

Introduction

Scaphoid fractures are often initially missed and then diagnosed only once nonunion manifests. Because the natural history of these fractures results in radiocarpal arthritis and ultimately midcarpal arthritis, they must be surgically treated. However, choice of treatment strategy is still controversial. The techniques range from less invasive, such as percutaneous fixation, to more invasive, such as autologous bone grafting from the iliac crest or vascularized bone grafts.

Surgical treatment of nonunions can be minimally invasive with arthroscopy. This simplifies postoperative recovery, reduces complications, and preserves the wrist's capsule–ligament complex, and thus the scaphoid's precarious vascularization.

Operative Technique

Patient Preparation and Positioning

The procedure is performed under regional anesthesia using a tourniquet. The patient's arm is secured to an arm board. Finger traps are used to apply 5 to 7 kg of traction along the arm's axis.

Radiocarpal and Midcarpal Exploration

The scope is introduced into the 6R portal and the shaver into the 3–4 portal. This approach allows the integrity of the scapholunate ligament to be verified. The quality of the cartilage at the proximal pole of the scaphoid and radial styloid process is also verified. If needed, radial styloidectomy can be performed arthroscopically at this point in the procedure (Chapter 6).

Arthroscopic treatment of the nonunion is performed via the midcarpal joint. The scope is introduced into the ulnar midcarpal (MCU) portal and instruments into the radial midcarpal (MCR) portal. The first phase of the arthroscopic procedure consists of complete synovectomy with a shaver.

Nonunion Site Preparation

The nonunion site will be visible or will appear as a bone fissure filled with fibrous tissue (**Fig. 19.1a, b**). This fissure can be located with a hook probe. The nonunion site is abraded with a curved curet, shaver, and/or bur in succession (**Fig. 19.2a, b**). The goal is to expose bleeding

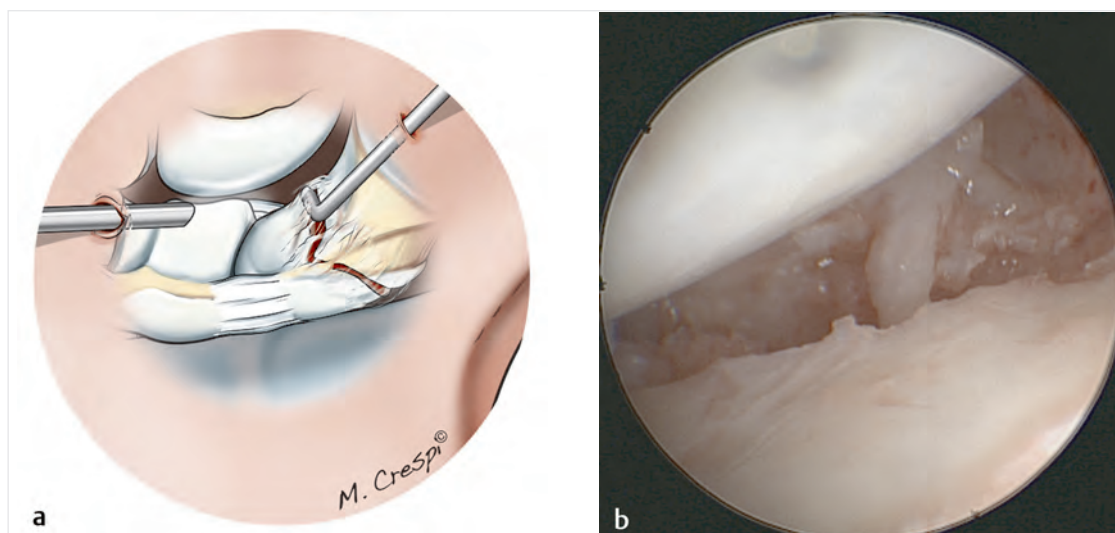


Fig. 19.1a, b

a Drawing of the nonunion site being palpated with a probe.

b Arthroscopic view of the nonunion site viewed from the midcarpal joint.

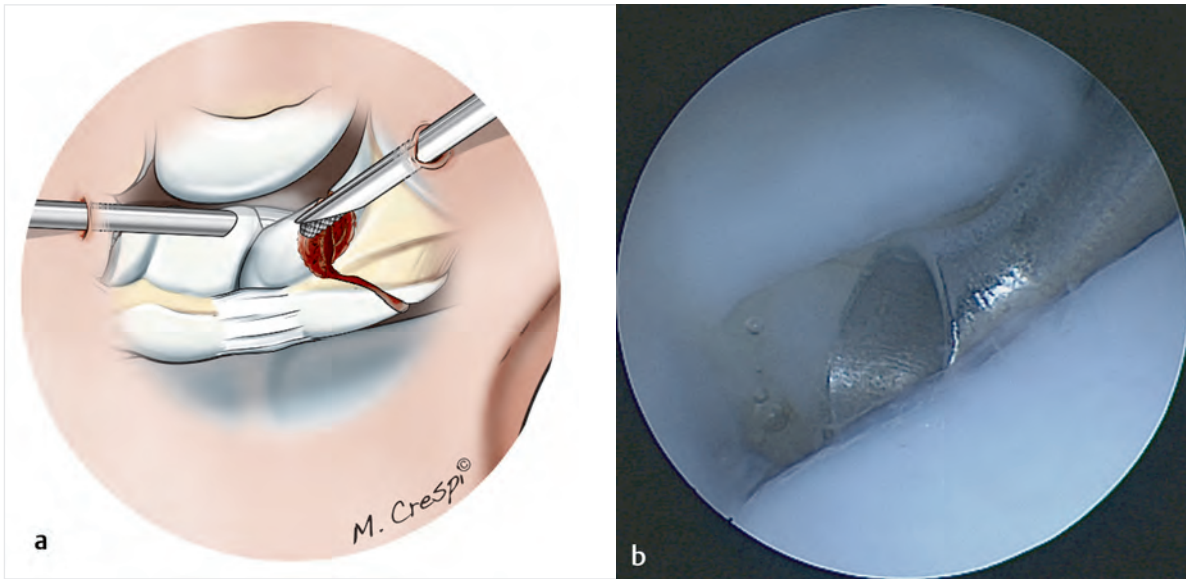


Fig. 19.2a, b

- a** Drawing of nonunion site being debrided with a bur inserted through the radial midcarpal (MCR) portal with the scope in the ulnar midcarpal (MCU) portal.
- b** Arthroscopic view of curettage of the nonunion site with the curet in the MCR portal and the scope in the MCU portal.

cancellous bone on both sides, visible by arthroscopy (Fig. 19.3).

Bone Graft Harvesting

The bone graft is harvested from the ipsilateral wrist. An incision is made on the lateral side of the wrist between

the first and second extensor compartments. The sensory branches of the radial nerve are identified and protected.

The periosteum under the extensor tendons in the first and second compartments is roughened with a bone rasp to free up the graft collection area. A three-sided osteotomy is performed while leaving a “bone cap” attached to the radius (Fig. 19.4). The bone graft is harvested with

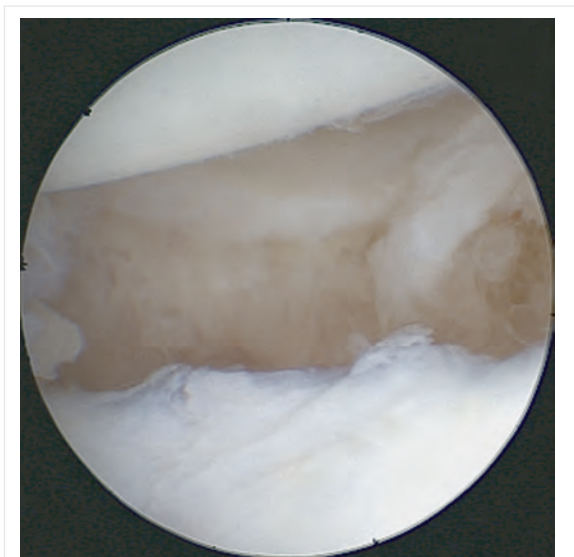


Fig. 19.3 Arthroscopic view of the abraded nonunion site after debridement.

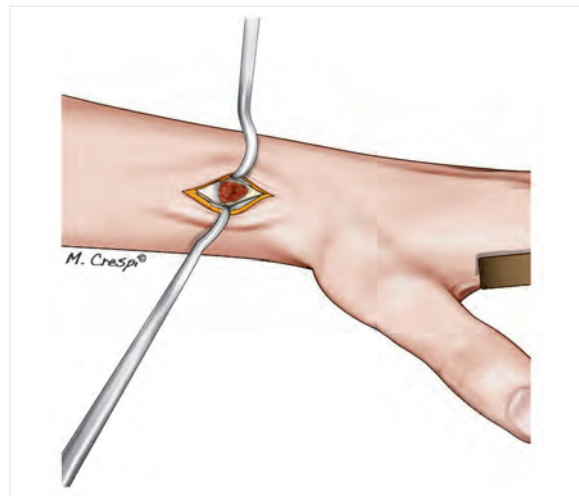


Fig. 19.4 Drawing of the bone graft harvesting site. Once the extensor tendons in the first and second compartments have been reflected below the periosteum, a cortical bone cap, still attached on its proximal side, is lifted, allowing access to the cancellous bone in the distal radius.

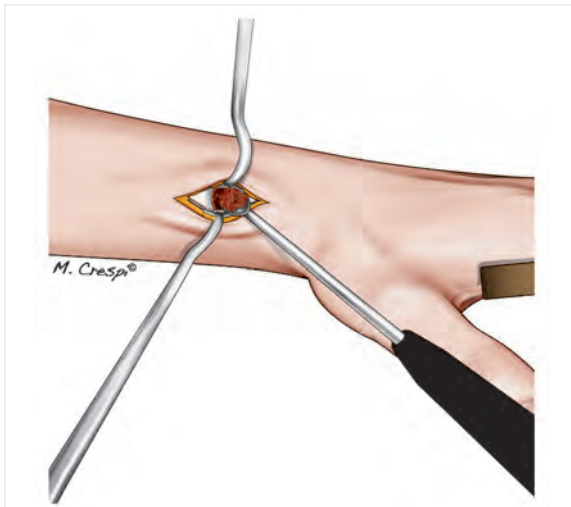


Fig. 19.5 Drawing of the graft being collected with a curet.

a curet; the graft's volume must be larger than the defect being filled (**Fig. 19.5**). After the graft has been collected, the cap is placed back onto the harvest site. The periosteum will spontaneously move back into place (**Fig. 19.6**). The skin is closed with interrupted sutures.

Temporary Fixation of the Nonunion

The abraded nonunion site is reduced and temporarily held in place with one or more K-wires (1 mm). This step can be performed with traction on the hand, or by setting

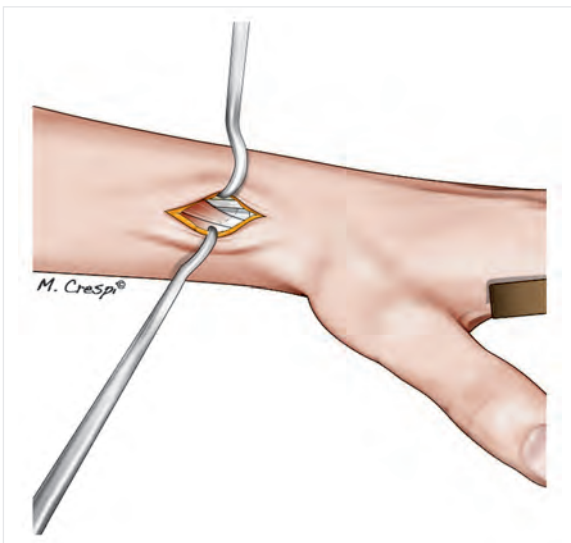


Fig. 19.6 Drawing of the two extensor compartments being repositioned once the cortical bone cap is replaced after graft collection.

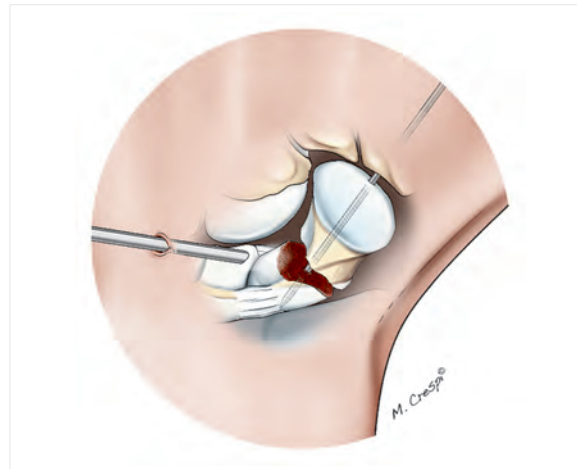


Fig. 19.7 Drawing of the scope in the midcarpal joint being used to verify the reduction after pinning.

the hand flat on the arm board if necessary. Reduction and K-wire positioning are verified by arthroscopy and fluoroscopy (**Fig. 19.7**).

Graft Implantation and Fixation

The next step is performed in a dry environment. If the initial part of the procedure was performed in a wet environment, all the fluid must be aspirated. The bone graft is inserted into a trocar, and the end of the trocar is placed at the nonunion site. The graft is pushed into the trocar with a blunt guidewire (**Fig. 19.8a–c**) until the nonunion site is filled. The bone graft is tamped down with a spatula (**Fig. 19.9**). At this point in the procedure, biological glue can be used to stabilize the grafts. Nevertheless, once the scaphoid is fixed and the traction released, the capitate bone's native anatomical position will provide sufficient graft stabilization.

Once the bone graft is in place, scaphoid fixation can be performed. If the nonunion is located in the scaphoid's body, the fragments are secured with a compression screw, preferably a self-tapping cannulated one, which is inserted through a small distal percutaneous incision. If the nonunion is at the proximal pole, stabilization can be improved by transcutaneous scapholunate pinning through a lateral incision. Two or three K-wires (1 or 1.2 mm) are inserted so their trajectories fix both the nonunion site and the scapholunate gap. The K-wires are buried under the skin (**Fig. 19.10a–c**).

Closure and Postoperative Care

The wrist is immobilized until union is achieved. Rehabilitation is initiated once the splint and/or K-wires have been removed.

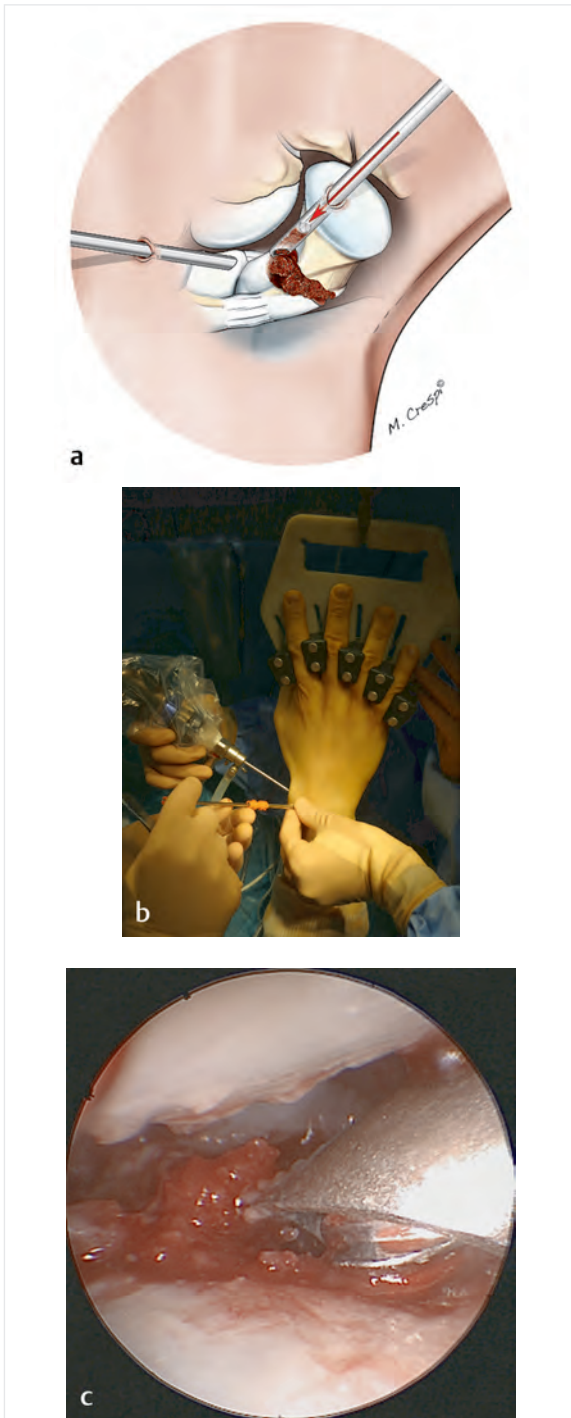


Fig. 19.8a–c

- a** Drawing of the graft being placed through a trocar inserted into the radial midcarpal (MCR) portal, with the distal tip placed at the nonunion site.
- b** Intraoperative view of the trocar placement and the graft being pushed down with a blunt guidewire. A bur is also visible.
- c** Arthroscopic view of the graft seated in the nonunion site, with the trocar in the MCR portal and the scope in the ulnar midcarpal (MCU) portal.

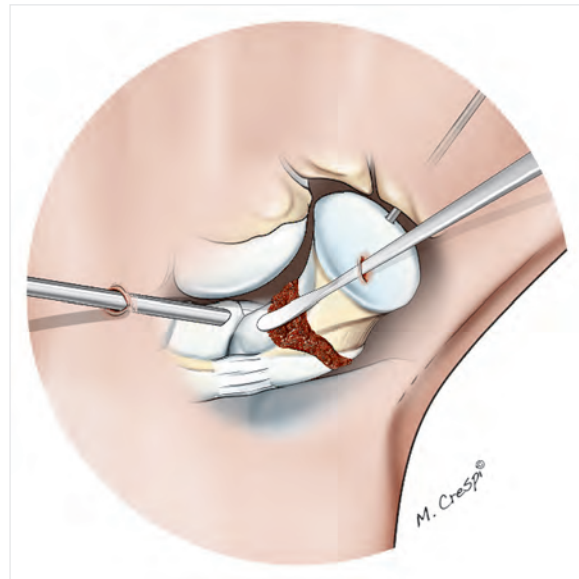


Fig. 19.9 Drawing showing the graft being tamped down with a spatula introduced through the radial midcarpal (MCR) portal.

Conclusion

Scaphoid nonunion is a common problem because the initial fracture can go undetected, and the bone is poorly vascularized. It can eventually progress to scaphoid nonunion advanced collapse (SNAC) and must be treated surgically before osteoarthritis sets in. Arthroscopic bone grafting is a simple, reliable technique that preserves vascularization, especially in patients with proximal pole nonunion.

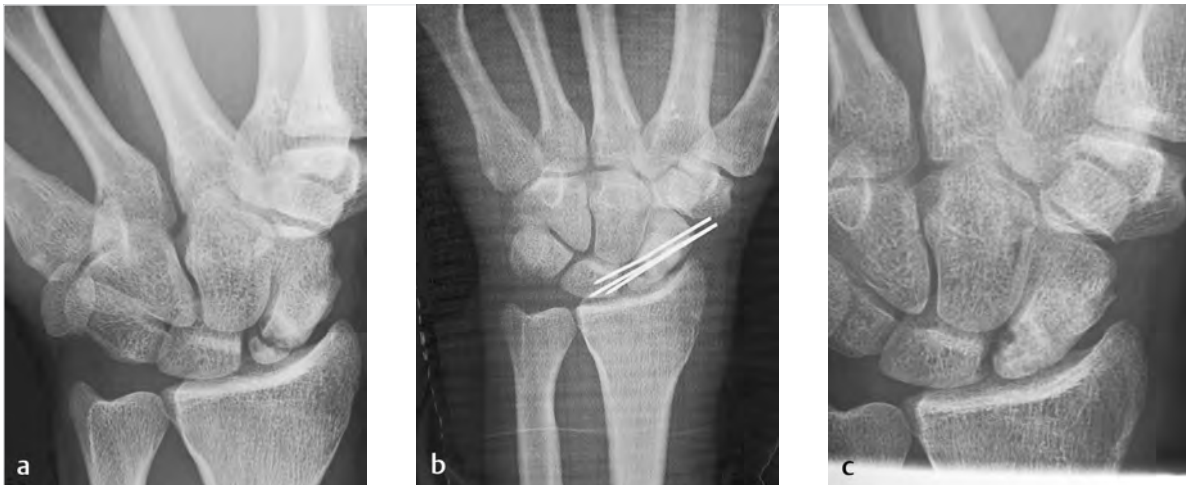

Fig. 19.10a–c

a X-ray of nonunion at the proximal pole of the scaphoid.

b Postoperative X-ray of the fixation construct consisting of triple scapholunate pinning that spans the scaphoid body, grafted nonunion site, proximal pole, and lunate.

c X-ray showing bone union 60 days after the K-wires were removed.