

# Chapter 14 Anatomy of the Scapholunate Complex

## Introduction

Scapholunate joint stability is ensured not only by the scapholunate interosseous ligament (SLIL) but also by a group of intrinsic and extrinsic elements called the scapholunate complex. A good understanding of this complex, based on technical advances and recent anatomical studies, is essential to providing timely, specialized care when it is injured, thereby giving it the best chance of healing. Such understanding requires pertinent information about the various structures involved.

This chapter precisely describes the topographic and arthroscopic anatomy of the scapholunate complex and the use of a hook probe to test the integrity of its various structures.

## Applied Anatomy and Biomechanics of the Carpal Ligaments

The proximal and distal interosseous ligaments, together with the volar and dorsal extrinsic ligaments, are directly involved in scapholunate stability.

During wrist flexion or extension, both rows of carpal bones flex or extend collectively but to differing degrees. The primary flexion and extension lines (where the joint is most mobile) cross at the scapholunate ligament. Distal carpal compression is the greatest at the capitate bone. As the pressure is transmitted to the proximal row, it tends to separate the scaphoid from the lunate.

## Intrinsic Ligament: Scapholunate Interosseous Ligament

The SLIL joins the scaphoid and lunate together. Its fibers are asymmetrical. The ligament consists of three separate, macroscopically continuous parts, at least before age-related degeneration sets in (Fig. 14.1a, b):

- Dorsal: acts as a dorsal ligament between the posterior horn of the lunate and the scaphoid
- Volar: thinner, but still strong
- Proximal (intermediate): little to no vascularity, thus cannot be repaired (similar to central part of triangular fibrocartilage complex [TFCC]); fibrocartilage between

the articular surfaces of the scaphoid and lunate (Fig. 14.2a, b)

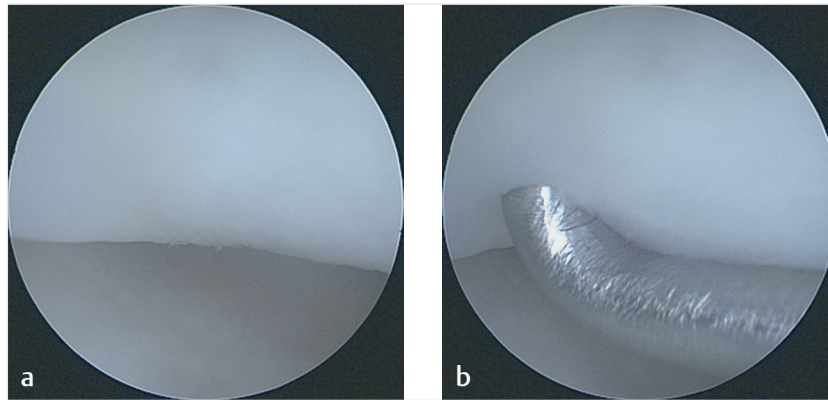
The dorsal portion is the strongest because of its thick, fibrous nature. It is considered the main scapholunate joint stabilizer.

## Extrinsic Ligaments

Some of the extrinsic wrist ligaments provide additional stabilization to the scapholunate joint:

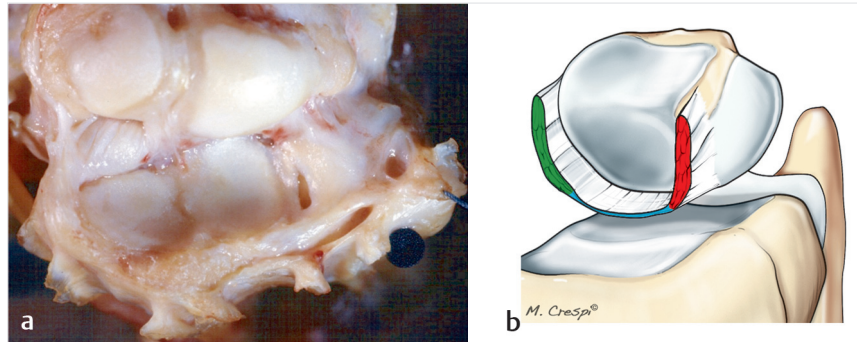
- The dorsal intercarpal (DIC) ligament seems to be the second most important stabilizer. The proximal portion of the DIC ligament is also called the dorsal scaphotriquetral ligament. Spanning the distal scaphoid and the triquetrum, it combines with the dorsal radiocarpal (DRC) ligament to form the “dorsal V” described by Senwald and Segmüller. It is unique in that it has multiple insertions onto the lunate and the scaphoid (Fig. 14.3).<sup>1</sup> This ligament complex, which restricts intracarpal supination and ulnar translation of the carpus, has a particularly high number of nerve endings. Together, this dorsal V and the dorsal portion of the SLIL form a network of dorsal ligament attachments.<sup>2</sup> Although this network’s length varies, it is always under tension, whether the wrist is in flexion or in extension.<sup>3</sup>
- In a recent cadaver study, the authors showed that this scapholunate confluence plays a major stabilizing role; we called this structure the dorsal capsulo scapholunate septum (DCSS).<sup>2</sup> The DCSS consists of a thickening of the capsule itself that connects the dorsal capsule with the dorsal portion of the scapholunate ligament (Fig. 14.4a, b).
- The volar radioscaphocapitate (RSC) ligament spans the radius and the capitate (Fig. 14.5a–c). It inserts deeply on the anterior side of the scaphoid’s waist (isthmus), restricts intracarpal pronation, and stops dorsal translation of the proximal pole. It makes up the radial branch of the distal palmar V.<sup>1</sup>
- The scaphotrapezial ligament stabilizes the radiovolar side of the scaphotrapezial joint. It is extremely strong and rarely tears.

Stability of the scapholunate joint is ensured by a combination of structures that constitute a ligament complex. The peripheral ends of the flexor and the extensor



**Fig. 14.1a, b**

- a** Arthroscopic view of an intact scapholunate ligament in a young patient. It is hard to distinguish the ligament from the articular surfaces of the lunate and scaphoid because they are seamlessly integrated; the scapholunate ligament can be detected only by the depression between the two bones.
- b** Arthroscopic view of the depression made by the probe in the scapholunate ligament.



**Fig. 14.2a, b**

- a** Anatomical study on a fresh cadaver showing the first row flexed 90° toward the radius after removal of all dorsal extrinsic ligaments (Pagliei). The intrinsic scapholunate interosseous ligament (SLIL) is located between the proximal pole of the cartilage-covered scaphoid (upper left) and the lunate.
- b** Drawing of the three portions of the scapholunate interosseous ligament (SLIL), in which red is the thick dorsal portion, blue is the thin, nonvascularized proximal (intermediate) portion, and green is the volar portion.

carpi radialis and ulnaris tendons further stabilize this complex by surrounding the carpus.

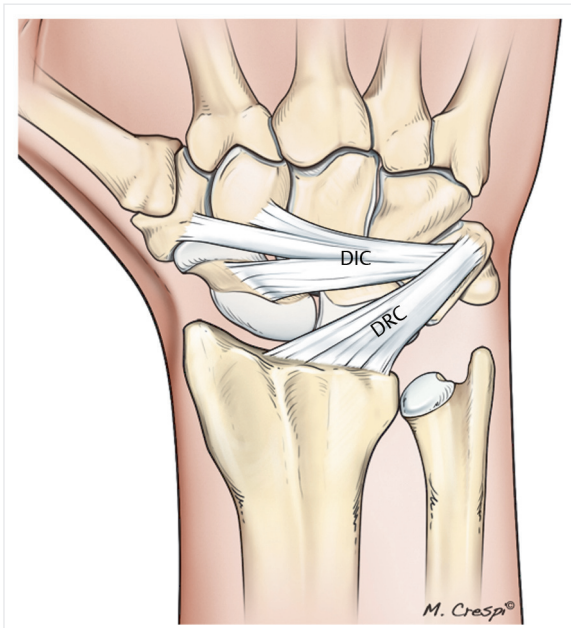
## Arthroscopic Testing of Scapholunate Stability—New Classification System

### Arthroscopic Testing of Predynamic Instability

Predynamic or occult instability is evidence of an incomplete tear that can be detected by arthroscopy. The

procedure is performed on an outpatient basis under regional anesthesia. The patient lies supine. Upward traction (5–7 kg) is applied to the arm, and a support pad is placed against the upper arm. A 30° scope is used for radial or midcarpal arthroscopy. A blunt trocar is essential to avoid damaging the cartilage and is inserted into portals once they have been located with needles. The standard radiocarpal (3–4 and 6R) and ulnar (ulnar midcarpal [MCU]) or radial midcarpal (MCR) portals are typically sufficient to assess proximal row stability. A hook probe is a critical tool for the testing.

Geissler and Dautel and Merle<sup>4,5</sup> separately proposed classification systems for arthroscopic predynamic scapholunate instability based on midcarpal testing with

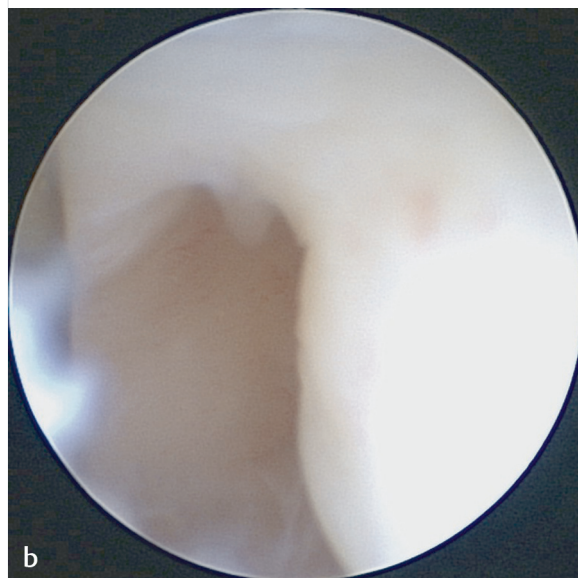


**Fig. 14.3** Drawing of the two dorsal extrinsic ligaments, the dorsal intercarpal (DIC) ligament and the dorsal radiocarpal (DRC) ligament.

a probe. This method was modified and improved by a European Wrist Arthroscopy Society (EWAS) group led by Messina.<sup>6</sup> The basic concept rests on determining if the scapholunate joint opens spontaneously or can be opened with a probe.

### European Wrist Arthroscopy Society Classification of Scapholunate Instability

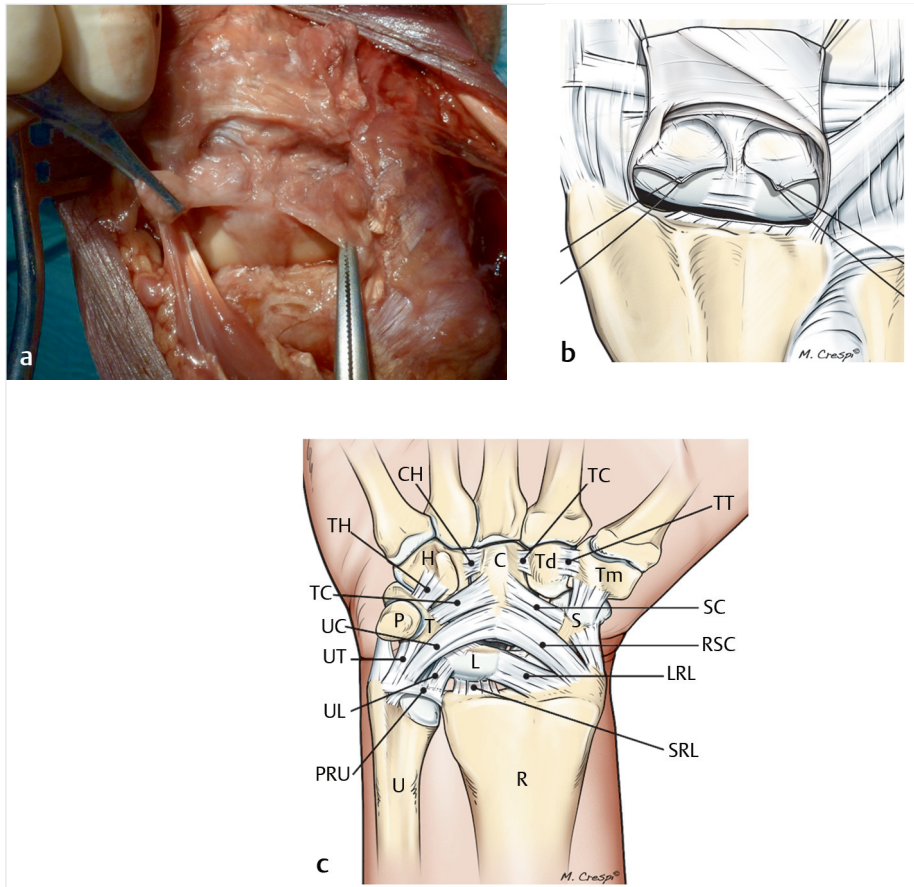
**Table 14.1** provides the EWAS classification system for scapholunate instability.<sup>7</sup> Stage I corresponds to a stable scapholunate joint; the probe cannot be inserted into the scapholunate joint space (**Fig. 14.6**). Stage II corresponds to a joint space that opens just enough to insert, but not rotate, the probe. Stage III corresponds to a larger opening of the joint space, which can be further widened by turning the probe, on either the volar side of the joint (IIIa) (**Fig. 14.7**), its dorsal side (IIIb) (**Fig. 14.8**), or in its entirety (IIIc). In stage IV, the joint opens spontaneously, which allows the scope to be moved from the midcarpal to the radiocarpal joint (**Fig. 14.9**). Stage V corresponds to major diastasis, visible on X-rays, with the scaphoid becoming horizontal.<sup>6</sup> Any opening of the scapholunate joint indicates that the SLIL is injured and that the extrinsic ligaments are acting as secondary scapholunate joint stabilizers. An isolated SLIL tear does not result in scapholunate instability unless an extrinsic ligament is also torn.



**Fig. 14.4a, b**

**a** Section of a cadaver wrist passing through the scapholunate ligament near the scaphoid. On the dorsal side, the DCSS is clearly visible between the dorsal capsule and the dorsal portion of the scapholunate ligament.

**b** Arthroscopic view of an intact dorsal capsulo-scapholunate septum (DCSS) located between the capsule and the dorsal portion of the scapholunate ligament.



**Fig. 14.5a–c**

- a** Cadaveric dissection.
- b** Drawing showing the DCSS, ligament structure composed of three arches uniting the dorsal capsule to the dorsal scapholunate ligament.
- c** Drawing of all the extrinsic volar ligaments. H, hamate; C, capitate; Td, trapezoid; Tm, trapezium; P, pisiform; T, triquetrum; L, lunate; S, scaphoid; U, ulna; R, radius; RSC, radioscaphocapitate ligament; LRL, long radiolunate ligament; SRL, short radiolunate ligament; UL, ulnolunate ligament; UT, ulnotriquetral ligament; UC, ulnocapitate ligament; TC, trapezocapitate ligament; SC, scaphocapitate ligament; PRU, volar part of triangular fibrocartilage complex.

## Arthroscopic Testing of Extrinsic Ligaments—Injury Classification

### Classification of Extrinsic Ligament Injury

Extrinsic ligaments are tested under the same conditions as already described for testing scapholunate stability in the midcarpal joint. Injuries are uncovered by visually inspecting the integrity of the structures and by using the probe to determine how tight they are. In some patients, the synovial membrane will have to be reflected or resected.

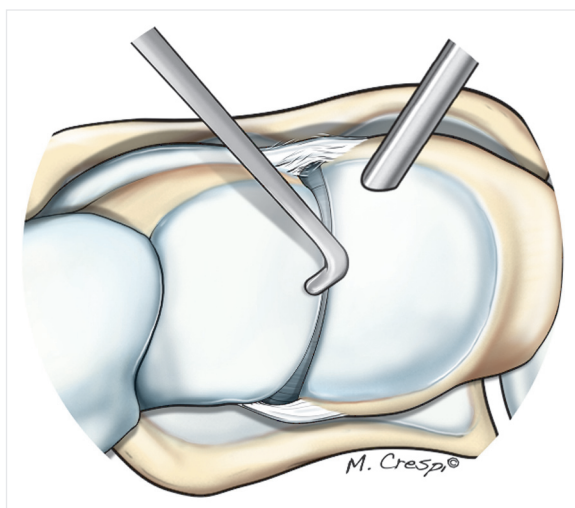
Four injury stages have been described<sup>7</sup>: (E0) the ligament is perfectly taut with all fibers continuous; (E1) the ligament is stretched and palpably lax, with more than 50% fiber continuity; (E2) the ligament is stretched and lax, with partial degeneration and < 50% fiber continuity; and (E3) the ligament is completely torn or is no longer present (Table 14.2).

### Method for Arthroscopic Testing of Extrinsic Ligaments

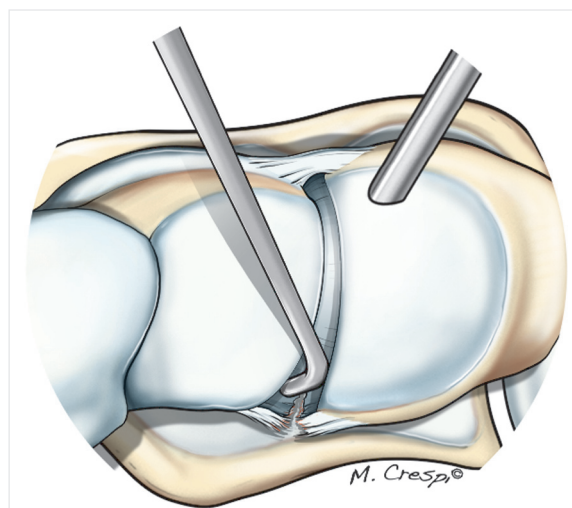
The testing sequence has been standardized and applies to all the dorsal and volar ligaments that can be accessed in the radiocarpal and midcarpal joints. Testing usually requires the four standard portals (3–4, 4–5, MCR, and

Table 14.1 Arthroscopic European Wrist Arthroscopy Society (EWAS) classification for scapholunate instability<sup>7</sup>

Stage	Arthroscopic findings	Associated injuries
Stage I	Probe cannot enter scapholunate (SL) joint	
Stage II	Tip of probe enters SL joint, without joint space widening	Proximal (membranous) part of scapholunate interosseous ligament (SLIL)
Stage IIIA	Partial volar widening of SL joint space on dynamic instability testing from midcarpal (MC) joint	Volar and proximal portions of SLIL with or without radioscaphocapitate (RSC)/long radiolunate (LRL) ligament injury
Stage IIIB	Partial dorsal widening of SL joint space on dynamic instability testing from MC joint	Dorsal and proximal portions of SLIL with complete tear of an extrinsic structure (dorsal intercarpal [DIC] or RSC/LRL ligament)
Stage IIIC	Complete widening of SL joint space during dynamic testing	Complete tear of SLIL (dorsal, proximal, and volar) with complete tear of one extrinsic structure (DIC or RSC/LRL ligament)
Stage IV	Spontaneous opening of SL joint space that allows scope to move from MC to radiocarpal (RC) joint	Complete tear of SLIL (dorsal, proximal, and volar) with complete tear of extrinsic structures (DIC and RSC/LRL ligament)
Stage V	SL diastasis visible on X-rays (dynamic or static)	Complete tear of SLIL, DIC, LRL, RSC, and at least one other ligament (triquetro hamatal [TH], scaphotrapezial [ST], DRC)



**Fig. 14.6** Drawing of Stage I scapholunate instability, viewed from above. The probe cannot be inserted between the scaphoid and lunate.

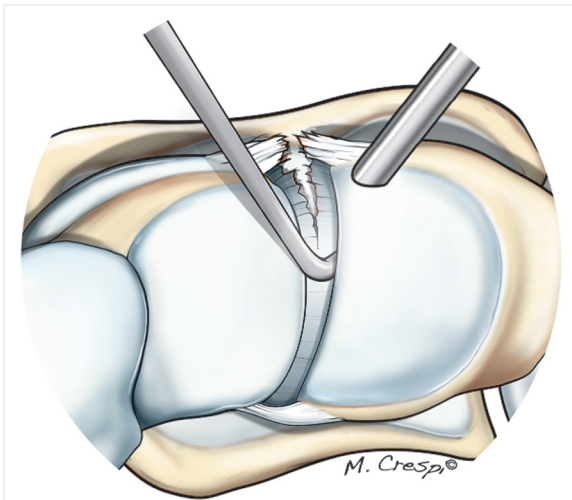


**Fig. 14.7** Drawing of Stage IIIa scapholunate instability, viewed from above. The probe can be inserted between the scaphoid and lunate, but only on the volar side; this is evidence of an isolated tear of the volar portion of the scapholunate ligament.

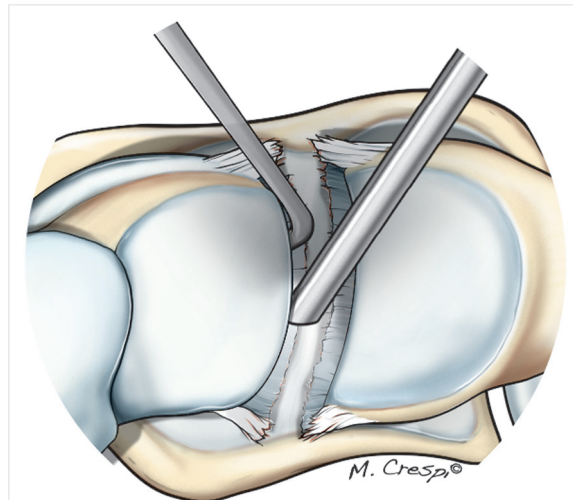
MCU) due to the scope angle and triangulation. In rare cases, the scaphotrapezotrapezoid (STT) portal may need to be used to visually confirm the DIC testing, or the 6U portal to visually confirm the DRC testing. The surgeon must be especially careful when using these latter portals given the presence of the radial artery and the sensory branch of the ulnar nerve.

### Extrinsic Ligaments Visible in the Radiocarpal Joint

The following ligaments are palpated sequentially in the radiocarpal joint with the scope in the 3–4 portal and the probe in the 6R portal: RSC, long radiolunate (LRL), short



**Fig. 14.8** Drawing of Stage IIIb scapholunate instability, viewed from above. The probe can be inserted between the scaphoid and lunate on the dorsal side; this is evidence of an isolated tear of the dorsal portion of the scapholunate ligament.



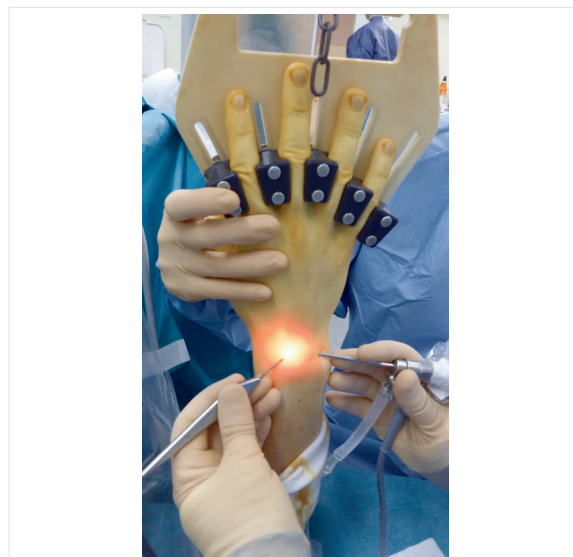
**Fig. 14.9** Drawing of Stage IV scapholunate instability, viewed from above. There is enough space between the scaphoid and lunate for the scope to pass easily between the two bones.

**Table 14.2** Arthroscopic classification of extrinsic ligament injuries

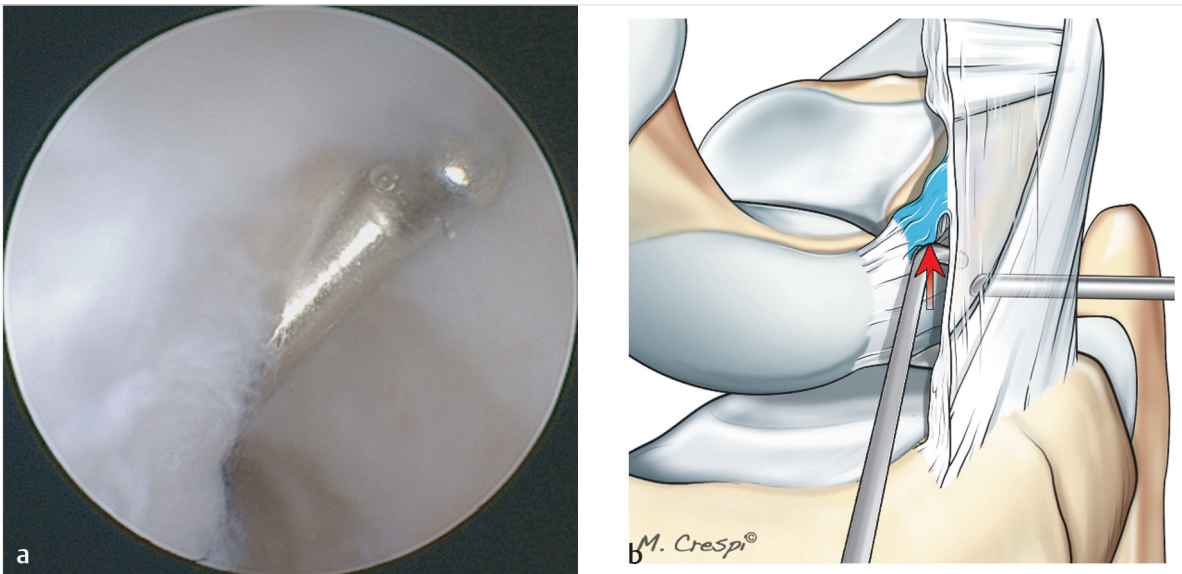
Stage	Arthroscopic findings
Stage E0	Ligament is perfectly taut with all fibers continuous
Stage E1	Ligament is stretched and palpably lax with > 50% fiber continuity
Stage E2	Ligament is stretched and palpably lax with < 50% fiber continuity
Stage E3	Ligament completely torn or no longer present

radiolunate (SRL), ulnolunate (UL), ulnotriquetral (UT), and dorsal radiocarpal (DRC) (Fig. 14.5). The RSC and LRL ligaments are easily palpated through the space between ligaments. The SRL can be palpated on the ulnar side of the ligament of Testut, but it is often hidden by synovium. The RSL has no mechanical role. The UL ligament is palpated immediately in front of the radial insertion of the triangular fibrocartilage complex (TFCC). The UT ligament is palpated immediately in front of the distal ulnar and palmar insertions of the TFCC. The DRC ligament is palpated by sliding the probe onto the proximal surface of the triquetrum and hooking the ligament’s dorsal insertion on the triquetral.

The DCSS is assessed by placing the scope in the 6R portal and the probe in the 3–4 portal (Fig. 14.10). With the scope, the dorsal capsule is followed over the SLIL until the DCSS is located; this is the ligamentous structure between the dorsal capsule and the dorsal portion of the SLIL. If the DCSS is intact, the probe will stop and remain in the radiocarpal joint (negative push test) (Fig. 14.11a, b). If the DCSS is torn, the probe will



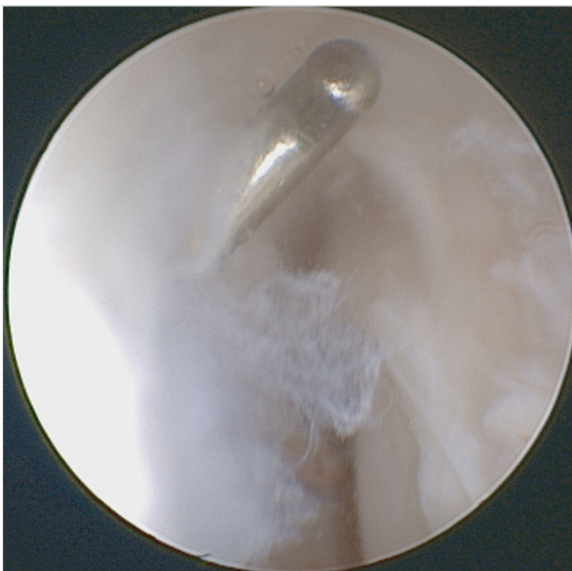**Fig. 14.10** Intraoperative view of instrument positioning used for DCSS testing. The scope is in the 6R portal and the probe in the 3–4 portal.



**Fig. 14.11a, b**

**a** Arthroscopic view during testing of an intact DCSS. The probe cannot go beyond the DCSS.

**b** Drawing of DCSS testing with a probe. The red arrow simulates the pressure from proximal to distal on the DCSS with the probe.



**Fig. 14.12** Arthroscopic view during testing of a torn DCSS. The probe is not hindered by the DCSS and can move into the dorsal part of the midcarpal joint.

breach the space between the dorsal capsule and the dorsal portion of the scapholunate ligament and will end up in the dorsal part of the midcarpal joint (positive push test) (**Fig. 14.12**).

### Extrinsic Ligaments Visible in the Midcarpal Joint

With the scope in the MCU portal and the probe in the MCR portal, the scapholunate and triquetrolunate joints are evaluated within the midcarpal joint. The scope is then introduced in the MCR portal and the probe in the MCU portal to sequentially test the scaphotrapezial (ST) ligament, the midcarpal portion of the RSC ligament, the triquetrocapitate (TC) ligament, and the DIC ligament.

The ST is palpated by placing the scope in the MCR portal and the probe in the MCR or STT portal. The probe crosses and passes over the scope inside the joint. It slides along the distal surface of the scaphoid and is pushed deep into the radial side of the STT joint. By following alongside the scaphoid, the scope can be advanced far enough to provide a direct view of the ligament in most patients.

The midcarpal portion of the RSC ligament is located in front of the scapholunate joint and is often covered by synovium. The UC ligament is the largest ligament in the anterior plane of the midcarpal joint and is located in front of the triquetrolunate joint. To palpate the DIC ligament, the probe is slid from volar to dorsal on the distal surface of the proximal third of the scaphoid. By pulling the scope almost out of the joint, the dorsal edge of the scaphoid can be viewed directly. The probe can hook the DIC ligament at this location and test both its scaphoid and lunate attachments. However, this latter ligament is

the hardest to test through the standard midcarpal portals and may require use of the STT portal.

## Conclusion

Scapholunate stability is effectively ensured by a complex associating the dorsal and volar portions of the SLIL, the DIC ligament, the DRC ligament, the RSC ligament, the ST ligament, and the DCSS. The integrity of these various stabilizers is considered when determining the arthroscopic classification of “predynamic” scapholunate instability.

Arthroscopic testing of extrinsic ligaments supplements the diagnosis of scapholunate instability while specifying the time frame of the injury through well defined criteria. From that point on, the choice of repair methods can be qualified. Given the information presented, it seems necessary to diagnose each injury and to treat as many stabilizing structures as possible when caring for patients with nonarthritic scapholunate instability.

## References

1. Sennwald G, Segmüller G. Anatomic basis of a new concept of stability of the carpus [in French]. *Int Orthop* 1986;10(1):25–30
2. Overstraeten LV, Camus EJ, Wahegaonkar A, et al. Anatomical description of the dorsal capsulo-scapholunate septum (DCSS)—arthroscopic staging of scapholunate instability after DCSS sectioning. *J Wrist Surg* 2013;2(2):149–154
3. Mitsuyasu H, Patterson RM, Shah MA, Buford WL, Iwamoto Y, Viegas SF. The role of the dorsal intercarpal ligament in dynamic and static scapholunate instability. *J Hand Surg Am* 2004;29(2):279–288
4. Geissler WB. Arthroscopic management of scapholunate instability [in French]. *Chir Main* 2006;25(Suppl 1):S187–S196
5. Dautel G, Merle M. Dynamic arthroscopic tests for the diagnosis of scaphoid-lunar instabilities [in French]. *Ann Chir Main Memb Super* 1993;12(3):206–209
6. Messina JC, Van Overstraeten L, Luchetti R, Fairplay T, Mathoulin CL. The EWAS Classification of Scapholunate Tears: An Anatomical Arthroscopic Study. *J Wrist Surg* 2013;2(2):105–109
7. Van Overstraeten L, Camus EJ. A systematic method of arthroscopic testing of extrinsic carpal ligaments: implication in carpal stability. *Tech Hand Up Extrem Surg* 2013;17(4):202–206