

Chapter 15 Dorsal Capsuloligamentous Repair of the Scapholunate Ligament Tear

Introduction

Scapholunate interosseous ligament (SLIL) tears are one of the most serious injuries associated with wrist trauma. Although open surgical repair can be performed, it is not indicated in the initial stages because of the resulting joint stiffness.

Wrist arthroscopy has changed how these injuries are diagnosed and treated. The injury can be evaluated in its initial stage, before the ligament is completely torn and the scaphoid becomes horizontal. The dorsal portion of the scapholunate (SL) ligament and its attachment to the dorsal capsule through a dorsal capsuloscapholunate septum (DCSS) are the keys to SL stability. This dorsal complex can be repaired arthroscopically using capsule-to-ligament suturing, thereby preventing the stiffness typically observed with open procedures.¹

Operative Technique

Patient Preparation and Positioning

The procedure is performed on an outpatient basis under regional anesthesia. The patient is placed supine, with the arm resting on an arm board with an attached tourniquet. Upward traction of 5–7 kg is applied to the hand.

Radiocarpal Exploration

The arthroscope and sheath are inserted through the 3–4 radiocarpal portal to visualize the SLIL. However, the dorsal portion of SLIL can be seen only with the scope in the 6R portal.

A shaver is introduced into the 6R portal to clean out the joint and perform a synovectomy. The shaver and arthroscope are reversed to finish the synovectomy, particularly at the dorsal recess. A probe is used to assess the nature of the SL ligament injury (Chapter 14). The scope can be used to follow the volar portion of the SLIL to its dorsal insertion. Usually the SLIL is avulsed from the scaphoid. The ligament stump that is attached to the lunate can easily be lifted with the probe. The dorsal portion of the SLIL and the DCSS are then evaluated at the dorsal recess. More often than not, the ligament is torn, with ligament stumps remaining attached to the scaphoid and lunate (**Fig. 15.1**). This technique can be performed only under these circumstances.

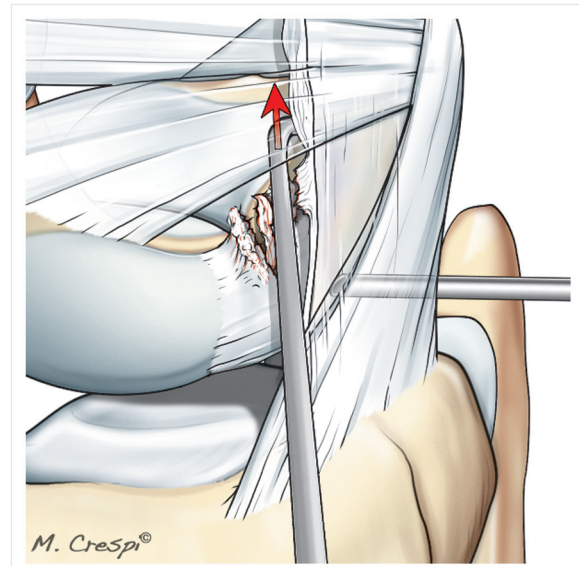


Fig. 15.1 Drawing of a torn scapholunate ligament. The probe indicates a positive push test with a torn DCSS. The red arrow shows the movement initiated by the probe from proximal to distal passing from RC joint to MC joint, because of the rupture of DCSS. The repair can be performed only if the scapholunate interosseous ligament remnants are attached to the lunate and scaphoid.

A push test is performed to assess the DCSS, which is an anatomical structure located between the dorsal intercarpal (DIC) ligament and the dorsal portion of the SL ligament. The probe is placed in the dorsal recess under scope guidance, using the angulation and triangulation effects. If the DCSS is intact, it will be completely visible, and the probe will not be able to advance. If the DCSS is not intact, the probe can subsequently move into the midcarpal joint without being hindered by the DCSS (positive push test) (Chapter 14).

Exploration of the Midcarpal Joint

The arthroscope and sheath are introduced through the ulnar midcarpal (MCU) portal. The shaver is introduced through the radial midcarpal (MCR) portal to carry out a synovectomy. In cases of dorsal intercalated segment instability (DISI), there will be a step-off between the scaphoid and lunate. The probe is inserted between the

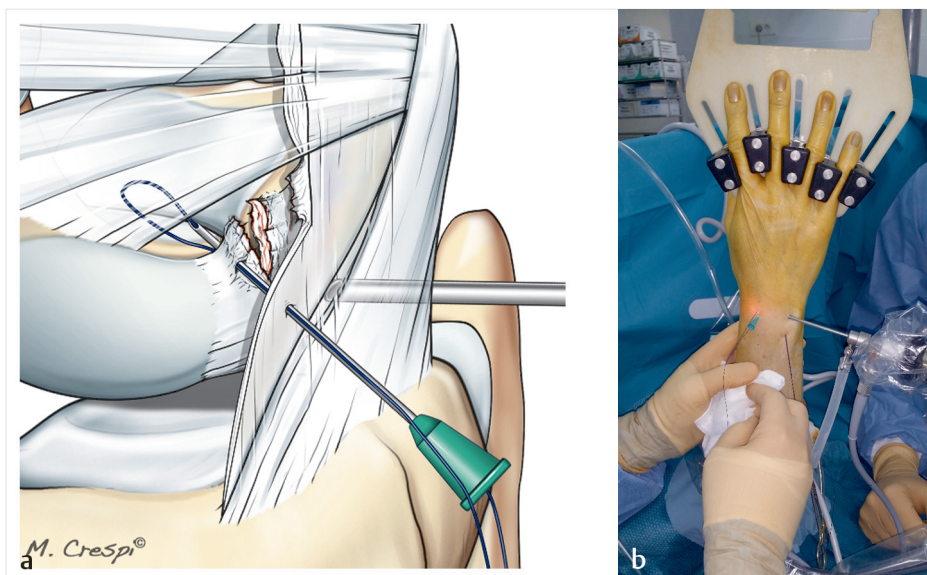


Fig. 15.2a, b

- a** Drawing of scapholunate ligament suture repair to the dorsal capsule. A suture is passed through a needle. The needle is inserted through the capsule and then through the dorsal portion of the scapholunate ligament that remains attached to the scaphoid.
- b** Intraoperative view showing positioning and alignment of the needle inserted through the 3–4 portal; in this specific patient, the sutures used to repair the triangular fibrocartilage complex beforehand are visible.

scaphoid and lunate to determine the dissociation stage (Chapter 14).

Performing the Dorsal Capsuloligamentous Suture

The scope is introduced into the 6R portal to inspect the gap between the lunate and the dorsal capsule. Absorbable monofilament suture (3–0 or 4–0 depending on the patient's size) is passed through a needle. This needle is inserted through the skin via the 3–4 portal, then shifted slightly distally to cross the joint capsule (**Fig. 15.2a, b**). The needle is localized inside the joint through the scope and then pushed through the SLIL stump on the scaphoid side. The needle is oriented dorsal to volar and angled proximal to distal, allowing it to enter the midcarpal joint (**Fig. 15.3**).

If the 3–4 portal is not exactly overlying the SLIL, the assistant can pull on the skin on the medial side of the wrist to shift the 3–4 portal and avoid having to make a larger opening (**Fig. 15.4**). A second needle and suture are then inserted parallel to the first into the SLIL stump attached to the lunate (**Fig. 15.5a–c**).

Tying the First Knot

The scope is returned to the MCU portal. The two needles are located inside the midcarpal joint, after they have passed between the scaphoid and lunate (**Fig. 15.6**). A hemostat

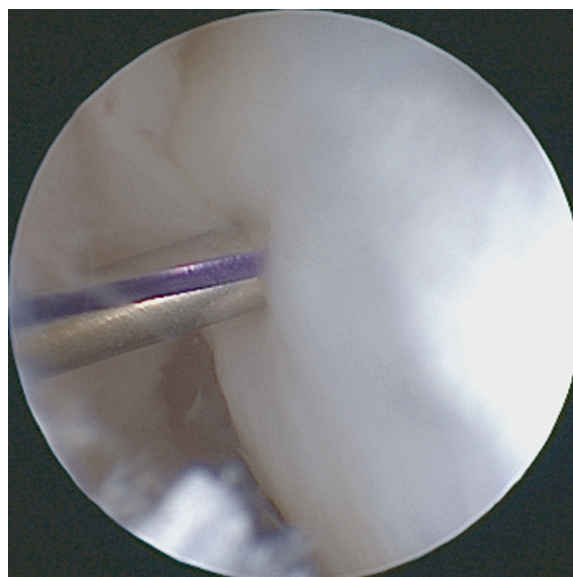


Fig. 15.3 Arthroscopic view of the needle passing through the capsule and dorsal portion of the scapholunate interosseous ligament (SLIL). The needle is angled dorsal to volar and proximal to distal so it can penetrate the midcarpal joint.

is introduced through the MCR portal to retrieve the two sutures (**Fig. 15.7a–c**). The needles are removed, and the hemostat is used to pull both sutures outside. A knot is tied between the two sutures (**Fig. 15.8**). Traction is applied to

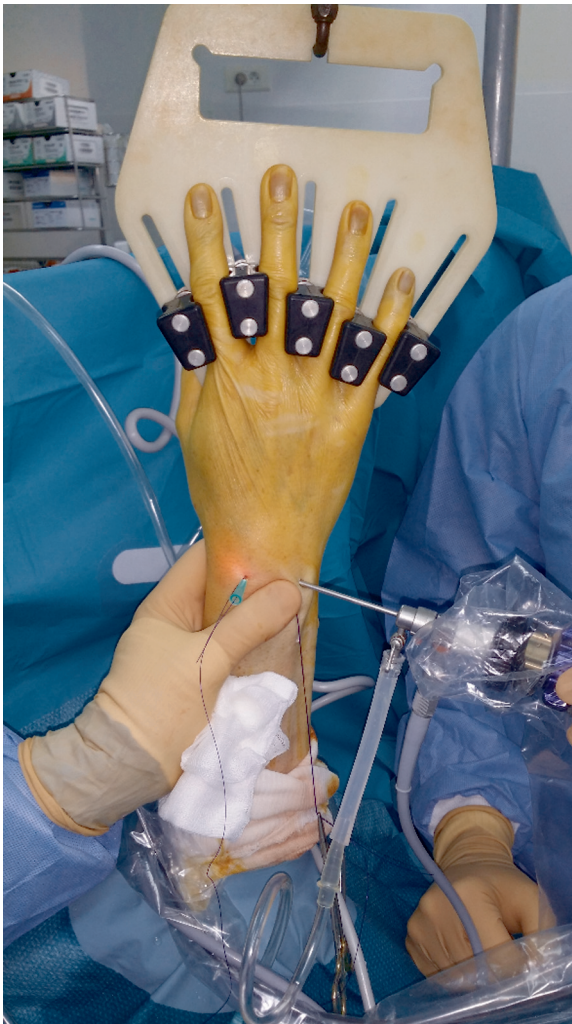

Fig. 15.4 Intraoperative view of a technical trick: by pulling on the skin on the medial side of the wrist, the 3–4 portal is shifted medially so it lies atop the SLIL.

both sutures through the 3–4 portal to pull the first knot into the midcarpal joint and seat it between the scaphoid and lunate (**Fig. 15.9a, b**). The knot is positioned volar to the remaining dorsal portions of the SLIL. The degree of reduction in the SL gap is determined by maintaining tension on the sutures and slightly releasing wrist traction. If reduction is satisfactory, the ligament is sutured to the dorsal capsule. If reduction is insufficient, K-wires will be needed stabilize the SL joint and potentially the scaphocapitate joint.

K-wire Fixation of the Scapholunate Joint (Optional)

K-wire fixation of the SL is challenging because of the small size of these bones. In some patients, a large dissociation

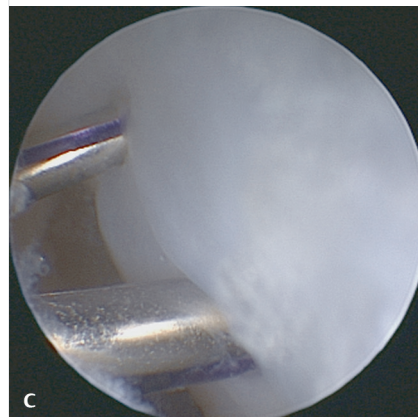
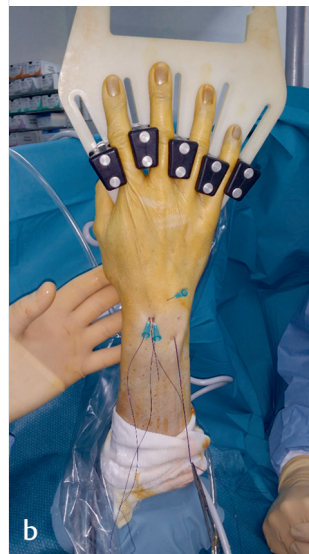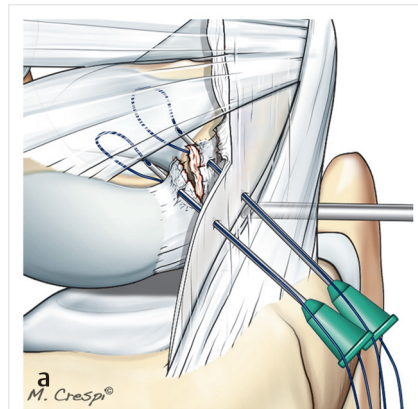


Fig. 15.5a–c
a Drawing showing the position of the two needles passing through the dorsal capsule into the two stumps of the dorsal portion of the scapholunate interosseous ligament.
b Intraoperative view of the position and alignment of the needles at this point in the procedure.
c Arthroscopic view of the position of the needles inside the joint.

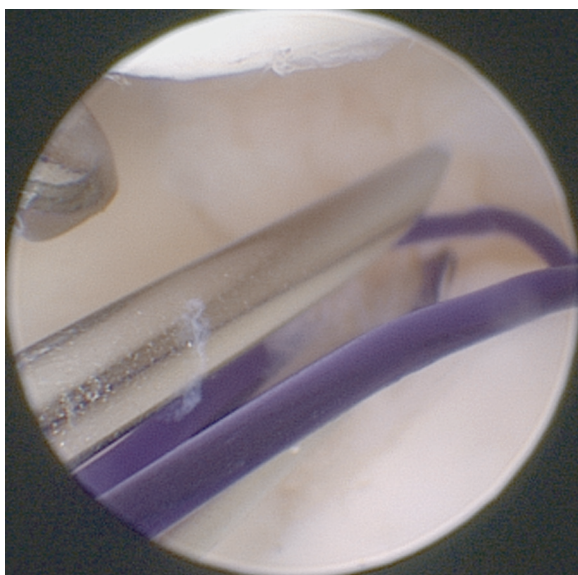


Fig. 15.6 Arthroscopic view of the two needles inside the midcarpal joint, between the scaphoid and lunate.

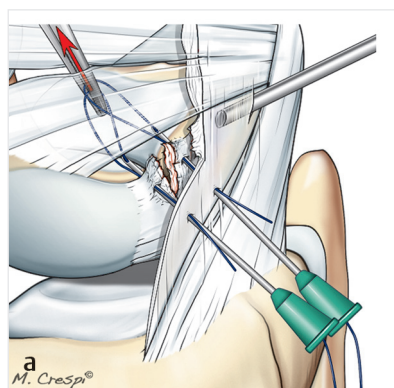
must be reduced. A blunt trocar guide is inserted through the MCR portal and then positioned under the capitate; the blunt tip will extend beyond the anterior edge of the proximal pole of the scaphoid. The scaphoid is reduced onto the lunate using a lever action in the manner of a tire iron (**Fig. 15.10**). The SL joint is secured while this position is maintained. When the blunt guide is removed, the scaphoid shifts back to its initial position and pulls the lunate back up. Scaphocapitate fixation may also be needed in cases of substantial dissociation (**Fig. 15.11**).

Tying the Second (Last) Knot

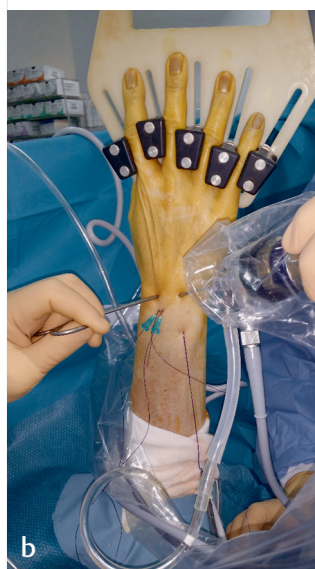The scope is returned to the 6R portal before the last knot is made. To ensure that the dorsal capsule–ligament suture is properly positioned, the dorsal capsule is pressed with the thumb while keeping the sutures taut; this roughly duplicates the final knot's action. Closing the gap re-creates the DCSS. A probe introduced through the 3–4 portal cannot be advanced distally. After the hand is released and the wrist is extended, the last knot is tied subcutaneously (**Fig. 15.12a, b**).

Postoperative Care

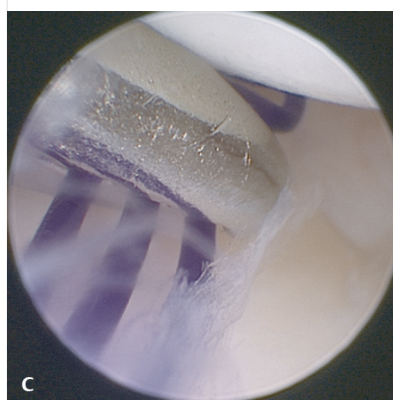
The portal incisions are not closed. The wrist is immobilized in extension (45–60°) with an anterior splint for 6 weeks in cases of suture repair only, and for 8 weeks in cases of associated K-wire fixation. The K-wires are removed after 8 weeks. Rehabilitation starts immediately after the immobilization period.



a
M. Cresp®



b



c

Fig. 15.7a–c

- a** Drawing of suture retrieval using a hemostat introduced through the radial midcarpal (MCR) portal.
- b** Intraoperative view of the position of the hemostat introduced through the MCR portal to retrieve the two sutures; the scope is in the ulnar midcarpal (MCU) portal.
- c** Arthroscopic view of the two sutures being retrieved by the hemostat.

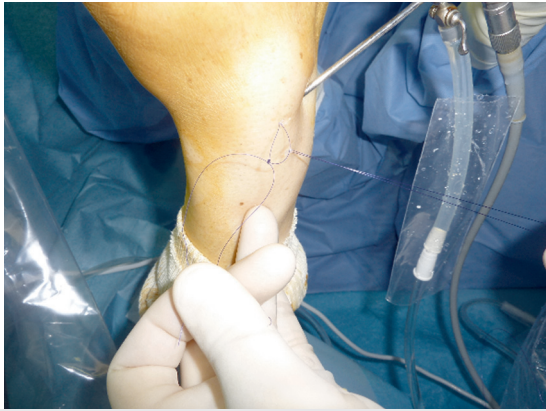

Fig. 15.8 Intraoperative view of the knot being tied between the two sutures while outside the wrist. The proximal suture ends have emerged from the 3–4 portal.

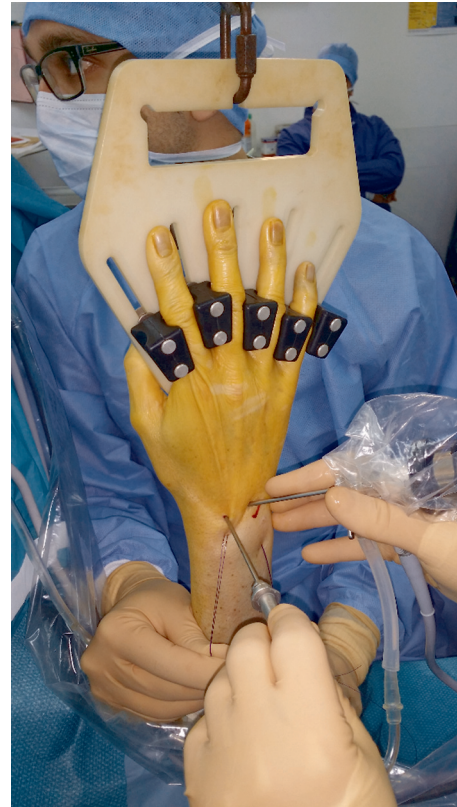

Fig. 15.10 Intraoperative view of significant scapholunate dissociation being reduced with a blunt trocar guide placed between the capitate and scaphoid, and then moved proximally using a “tire iron” leverage principle.

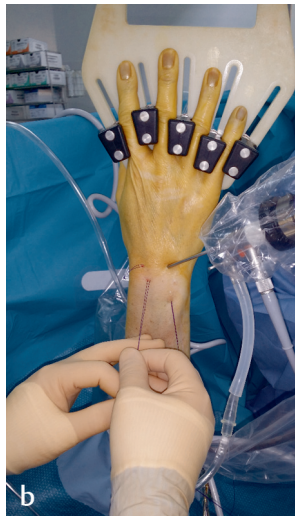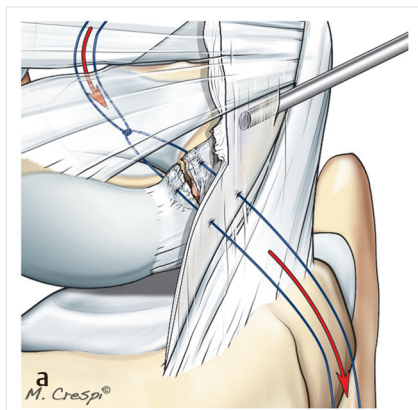


Fig. 15.9a, b
a Drawing of traction placed on the proximal suture ends to bring the knot back into the joint.
b Intraoperative view showing traction on the proximal suture ends.

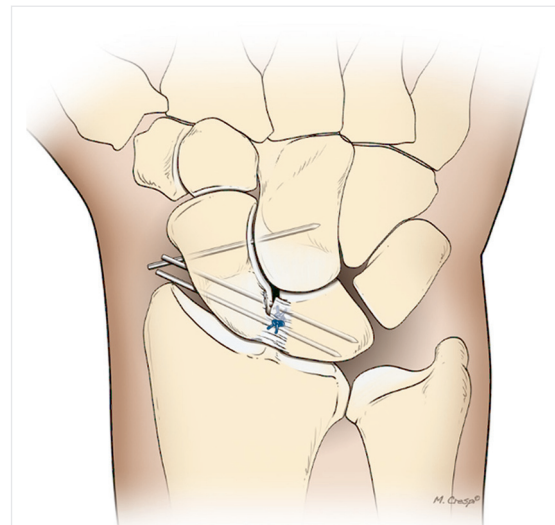


Fig. 15.11 Drawing of the K-wire fixation step; when significant reduction is needed, two K-wires are inserted through the scaphoid and lunate and one through the scaphoid and capitate.

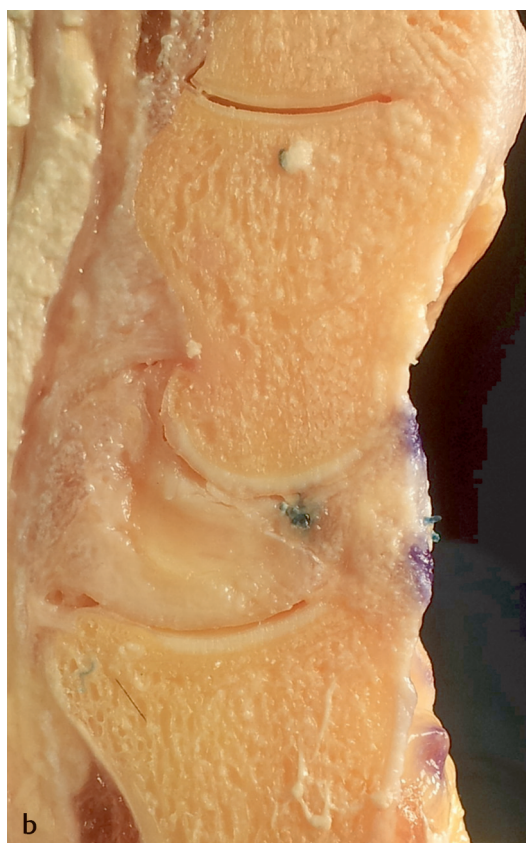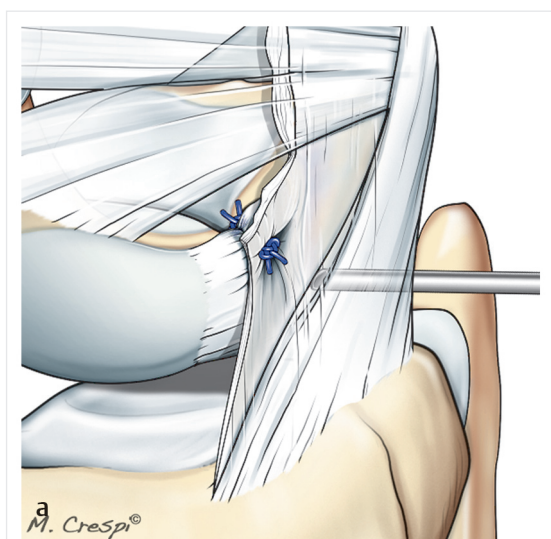


Fig. 15.12a, b

- a** Drawing of the suturing between the scapholunate and dorsal capsule with one intra-articular knot located in front of the dorsal portion of the scapholunate interosseous ligament and one extra-articular subcutaneous dorsal knot located behind the dorsal capsule.
- b** Section through a cadaver wrist showing the thickness of the repair after the ligament and dorsal capsule have been sutured.

Conclusion

Arthroscopic repair of the SLIL has drastically changed how SL injuries are treated. The resulting repairs are excellent. This method avoids the stiffness typically associated with open procedures. Athletes are able to return to preinjury performance levels. Nevertheless, its use is limited to patients in whom the stump of the dorsal portion of the SLIL is still attached to the scaphoid. Arthroscopy and comprehensive clinical assessments can provide early diagnosis of SL tears, leading to early treatment.

Reference

1. Wahegaonkar AL, Mathoulin CL. Arthroscopic dorsal capsulo-ligamentous repair in the treatment of chronic scapho-lunate ligament tears. *J Wrist Surg* 2013;2(2):141–148