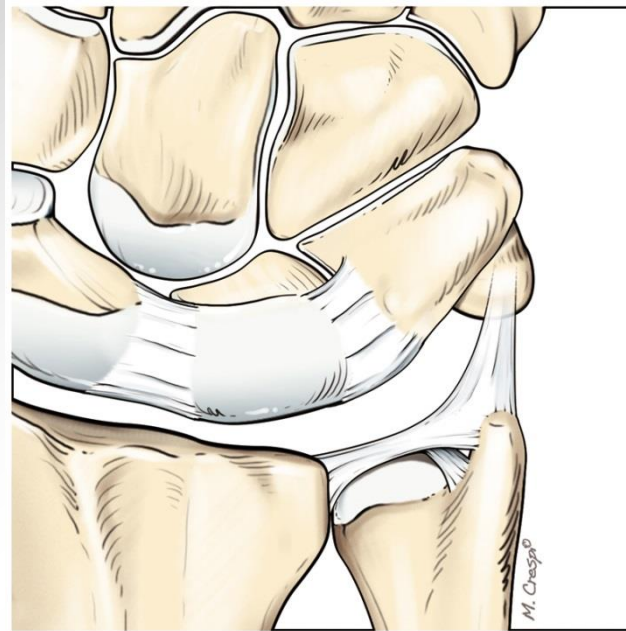


# DISTAL RADIO-ULNAR JOINT ARTHRITIS

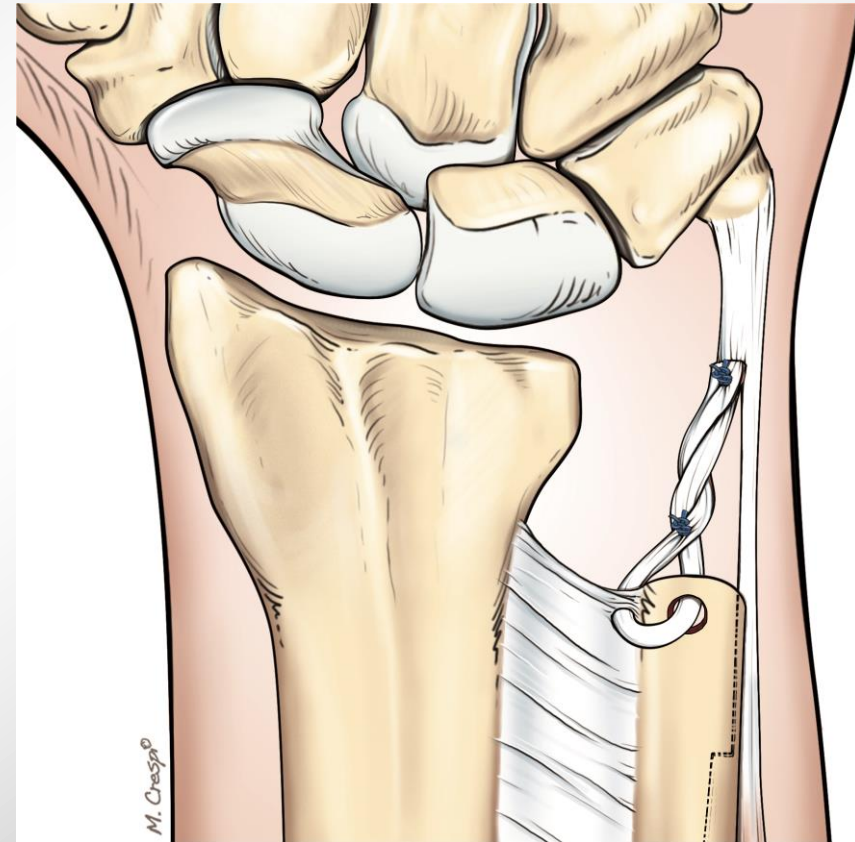
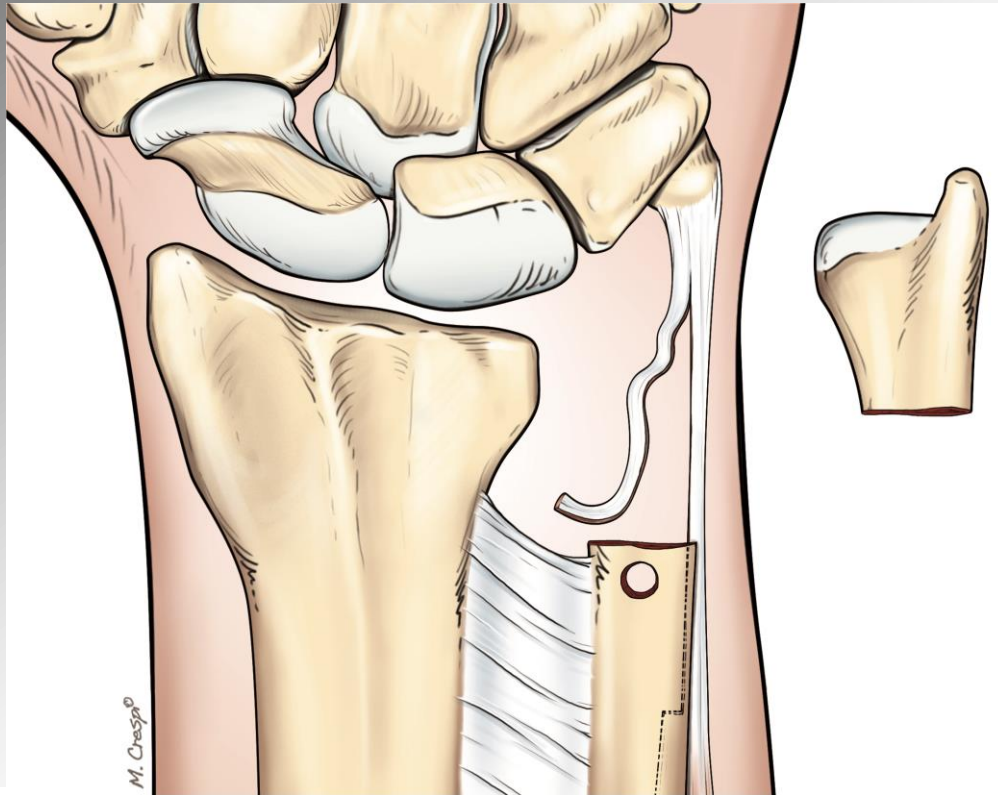


Ch. Mathoulin  
Institut de la main, Paris



# Treatment options

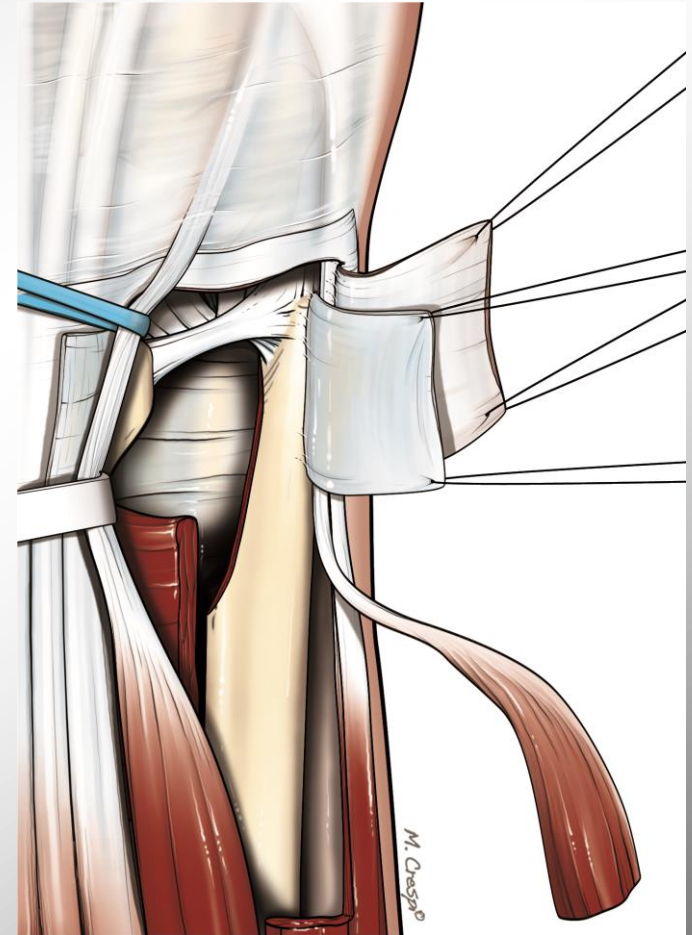
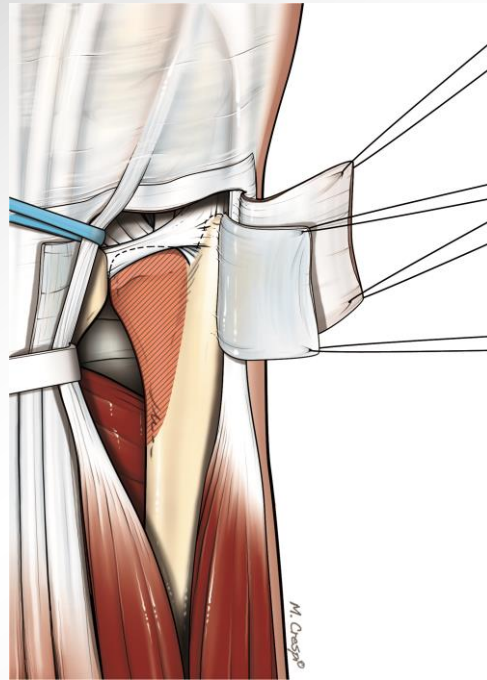
Darrach's procedure (1913) the simplest, but...



# Treatment options

## Hemi-resection

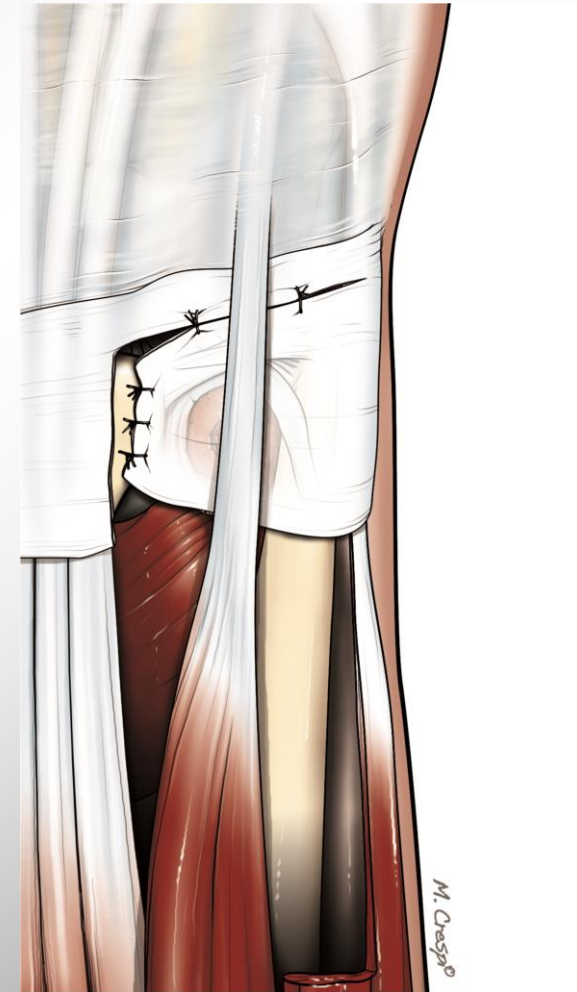
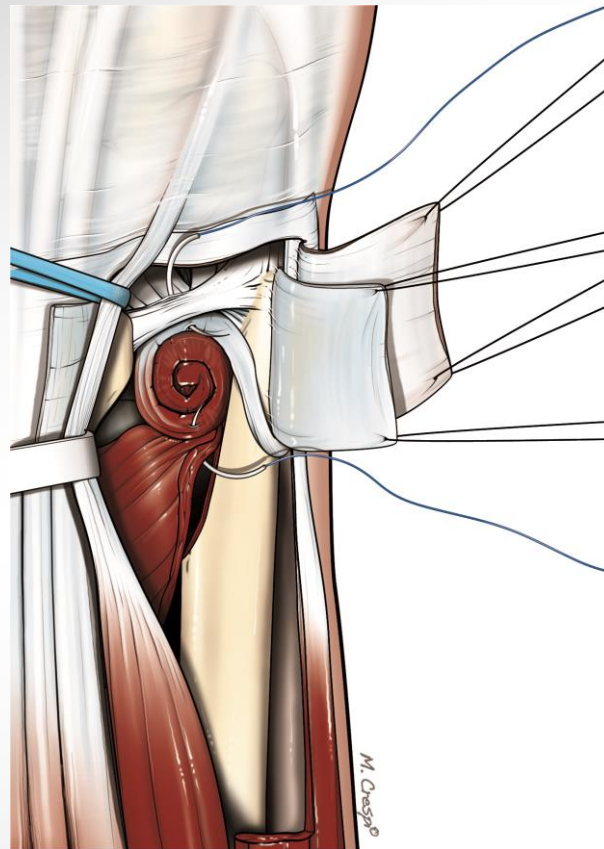
- BOWERS 1985
- FERNANDEZ 1988
- Dorsal approach



# Treatment options

## Hemi-resection

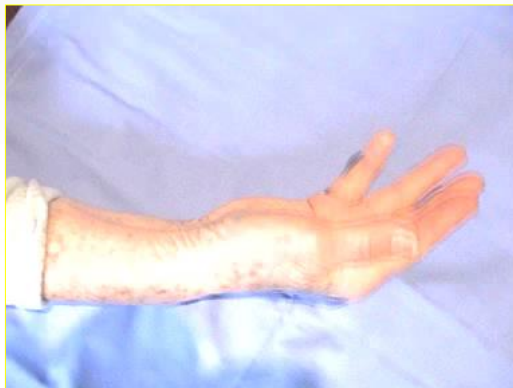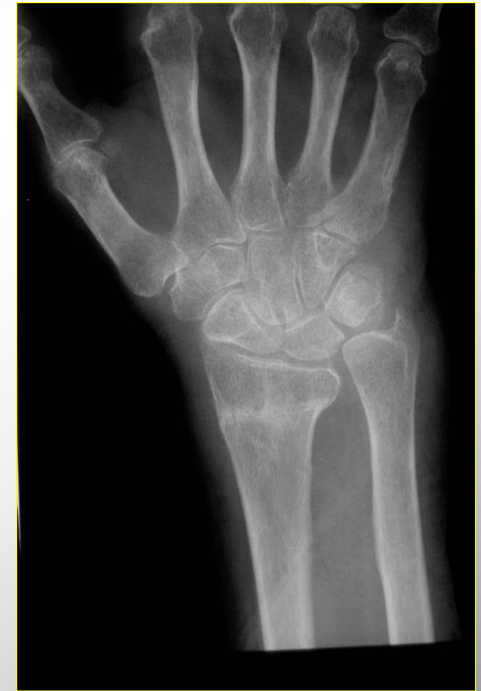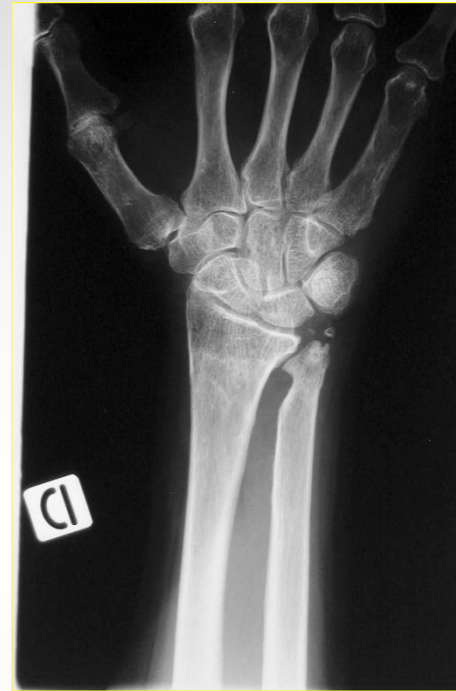- BOWERS 1985
- FERNANDEZ 1988
- Dorsal approach



# Treatment options

## Hemi-resection

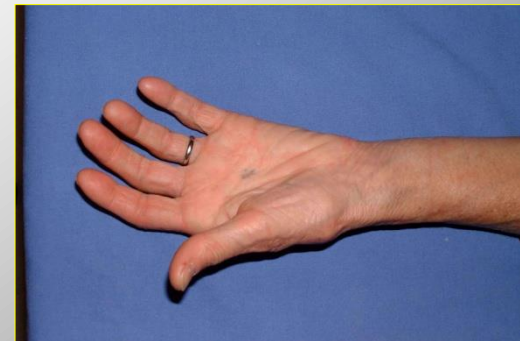
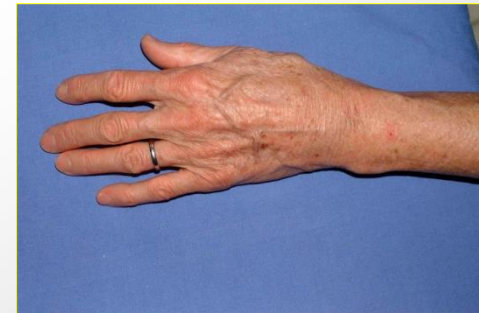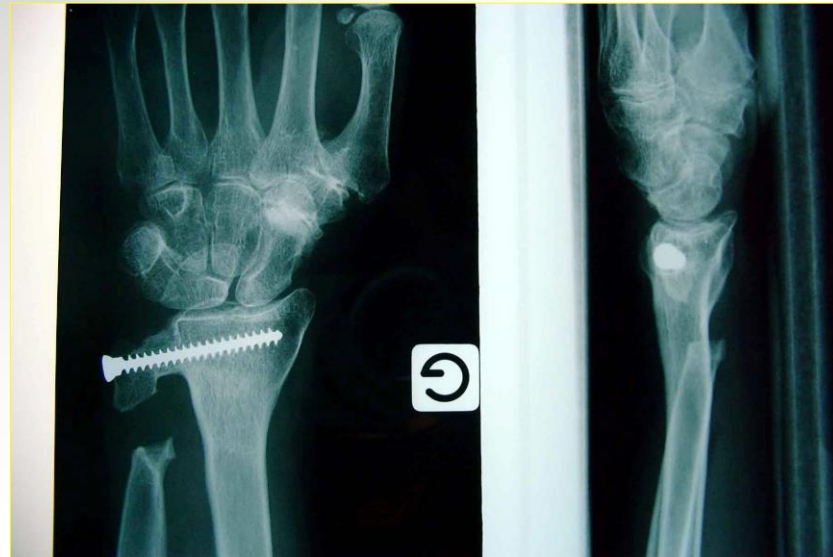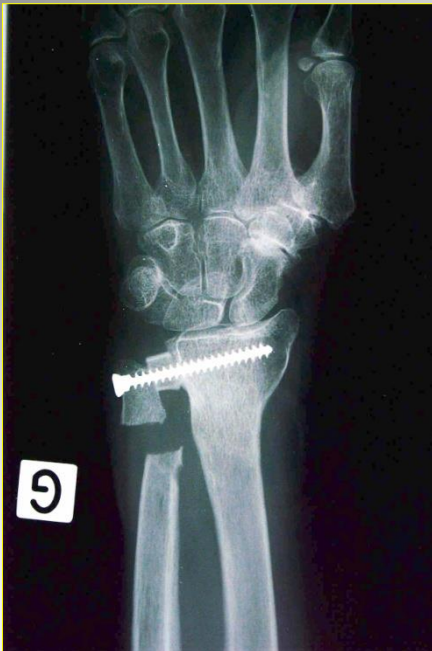- BOWERS 1985
- FERNANDEZ 1988
- Dorsal approach



25 years of follow-up...

# Treatment options

## Sauvé-Kapandji



# Treatment options

## Distal ulnar head prosthesis

Figure 2 – First clinical case after the operation: the patient underwent resurfacing distal arthroplasty of the ulna.

