

Chapter 12 Distal Ulnar Resection

Introduction

Ulnar impaction syndrome is a common but often unrecognized cause of pain on the ulnar side of the wrist. Although it can be congenital (due to a long ulna), it is most often secondary to a distal radius fracture with axial subsidence, especially in older patients. This proximal shift in the radial epiphysis leads to the appearance of a "long ulna," which translates to positive ulnar variance (Fig. 12.1a-c). Pain is often exacerbated during forced

radial deviation, which causes the lunate to slide toward the ulnar head. The resulting injuries appear in succession over time: perforation of the radioulnar disk of the triangular fibrocartilage complex (TFCC) ligament, impingement between the distal ulna and medial aspect of the proximal lunate, and, eventually, lunotriquetral instability or even chondromalacia of the head of the hamate (Fig. 12.2a, b). Several treatments are possible, such as ulnar shortening, radial reconstruction osteotomy, and ulnar head resection. Arthroscopic distal resection of the

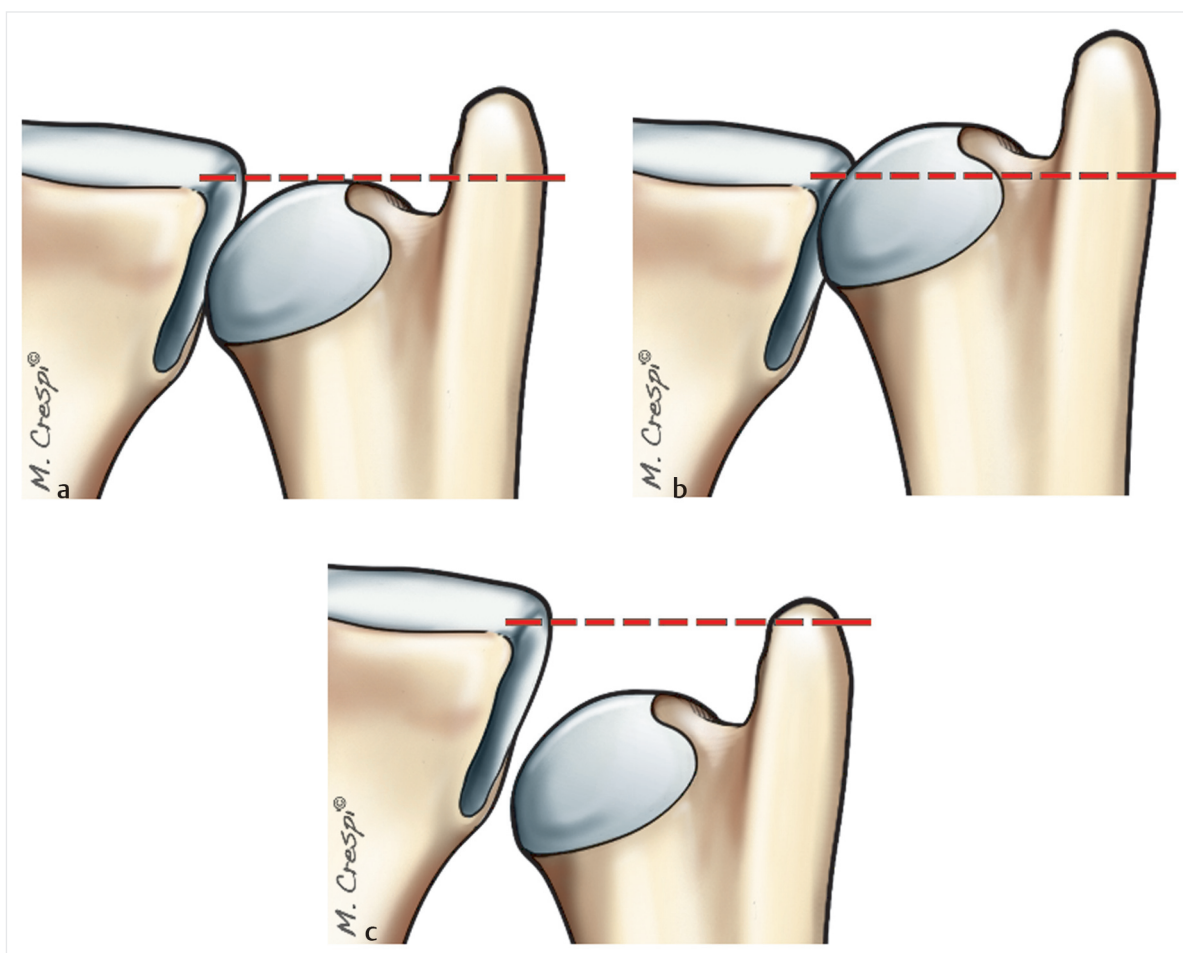


Fig. 12.1a-c

- a Drawing of the typically normal relationship between the ulnar head and distal radius (neutral ulnar variance).
- b Drawing of a positive ulnar variance where the ulna is longer than the radius.
- c Drawing of a negative ulnar variance where the ulna is shorter than the radius.

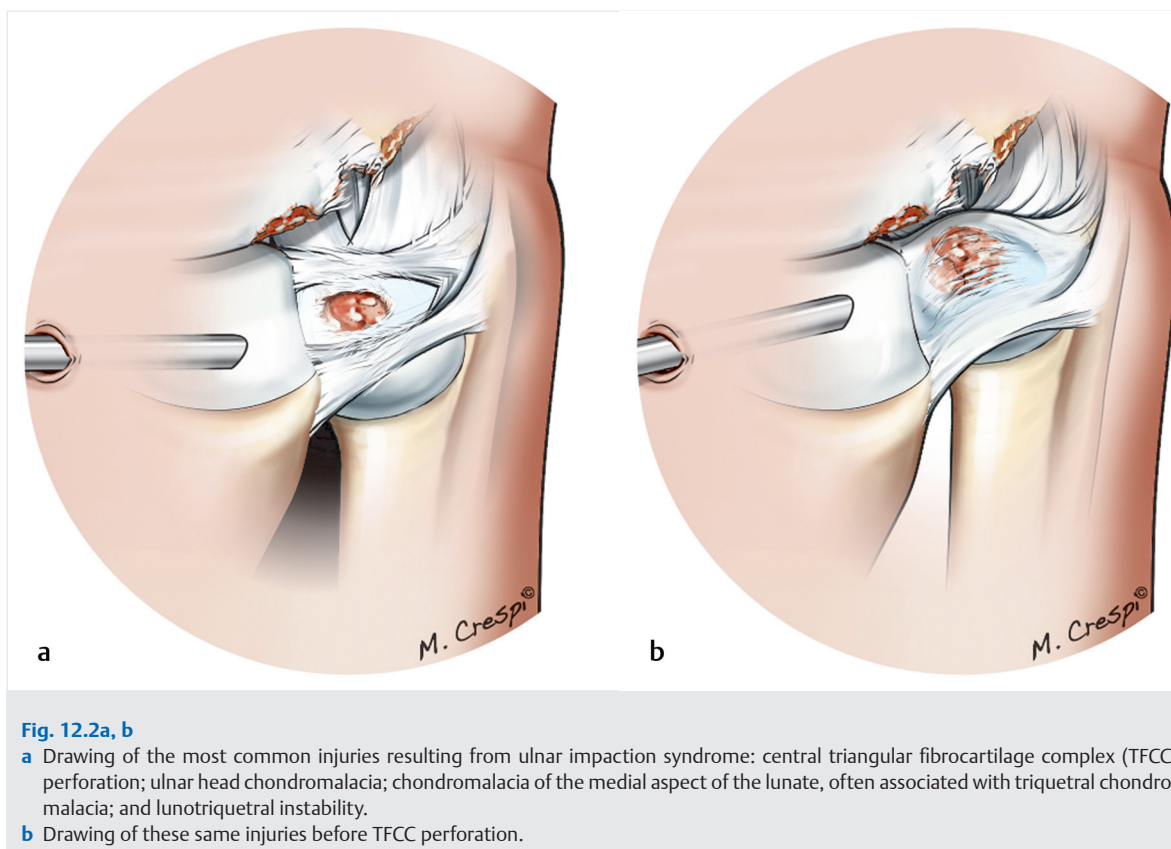


Fig. 12.2a, b

- a** Drawing of the most common injuries resulting from ulnar impaction syndrome: central triangular fibrocartilage complex (TFCC) perforation; ulnar head chondromalacia; chondromalacia of the medial aspect of the lunate, often associated with triquetral chondromalacia; and lunotriquetral instability.
- b** Drawing of these same injuries before TFCC perforation.

ulnar head is a simple surgical technique that eliminates impingement without requiring wrist immobilization.

Operative Technique

Patient Preparation and Positioning

The procedure is performed under regional anesthesia with the patient supine and the arm abducted to 90° and resting on a hand table. A tourniquet is placed at the base of the arm and secured to the table. The elbow is flexed to 90°, and 5 to 7 kg of traction is applied using finger traps.

Exploration and Synovectomy of the Radiocarpal Joint

The arthroscope is introduced through the 3–4 radiocarpal portal; the 6R radiocarpal portal is used to pass instruments. The first exploratory step always consists of debridement of the inflamed synovial membrane with a shaver. This provides good exposure of the TFCC ligament and ensures that no synovial remains will be interposed in front of the scope or interfere with the resection step.

Preparation of the Triangular Fibrocartilage Complex Ligament

In the second step the central TFCC ligament is debrided. Extensive debridement may not be necessary if the central portion is already significantly perforated, due either to the chronic nature of the impingement or to the degenerative nature of the perforation in an older patient. This central perforation, which is usually present, is widened using basket forceps and then evened out with a shaver to expose the ulnar head cartilage (Fig. 12.3). A radiofrequency ablation probe can also be used to make this step easier. Any chondromalacia of the ulnar head is now visible (Fig. 12.4).

Distal Ulnar Resection

The next step is the bone resection itself. The entire visible portion of the ulnar head jutting out above the radius is resected with a bur (Fig. 12.5a, b). Note that the ulnar head is oval rather than spherical. As a consequence, the surgical assistant must pronate and supinate the wrist during the burring. The surgeon continues the resection as new bulges appear (Fig. 12.6a, b). During this

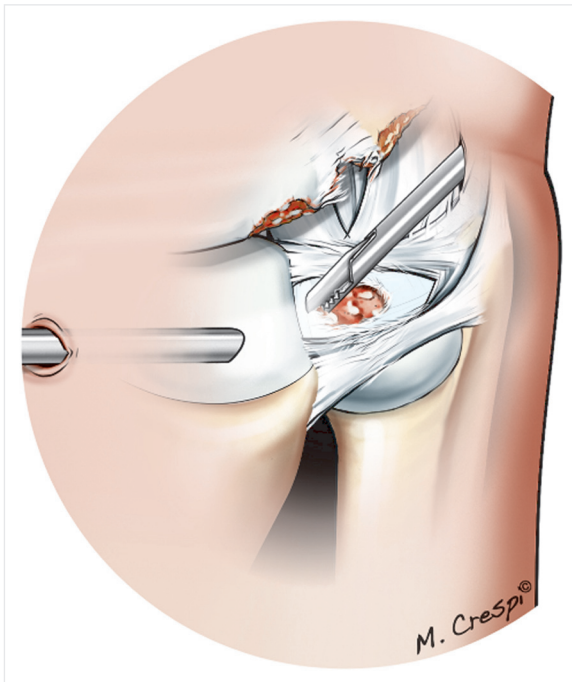


Fig. 12.3 Drawing of central debridement of the triangular fibrocartilage complex (TFCC) using basket forceps. Care must be taken to avoid injuring the peripheral structures because they stabilize the TFCC.

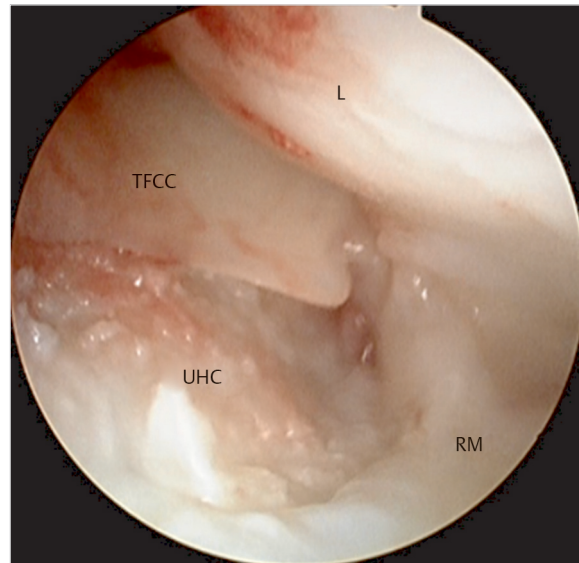


Fig. 12.4 Arthroscopic view of damaged ulnar head cartilage through the central triangular fibrocartilage complex (TFCC) perforation. L, lunate; UHC, ulnar head cartilage; RM, radius medial aspect.

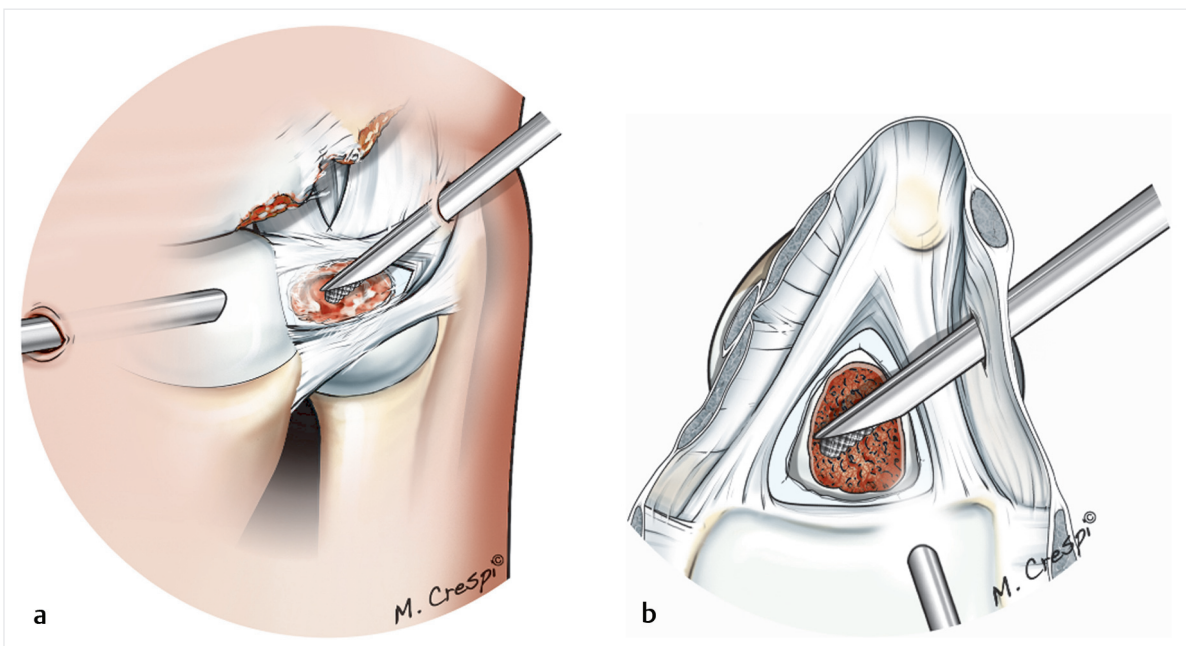


Fig. 12.5a, b
a Drawing of the burr position in the 6R portal and initial resection of the ulnar head through the visible central portion.
b Drawing of the view from above the same configuration seen in (a).

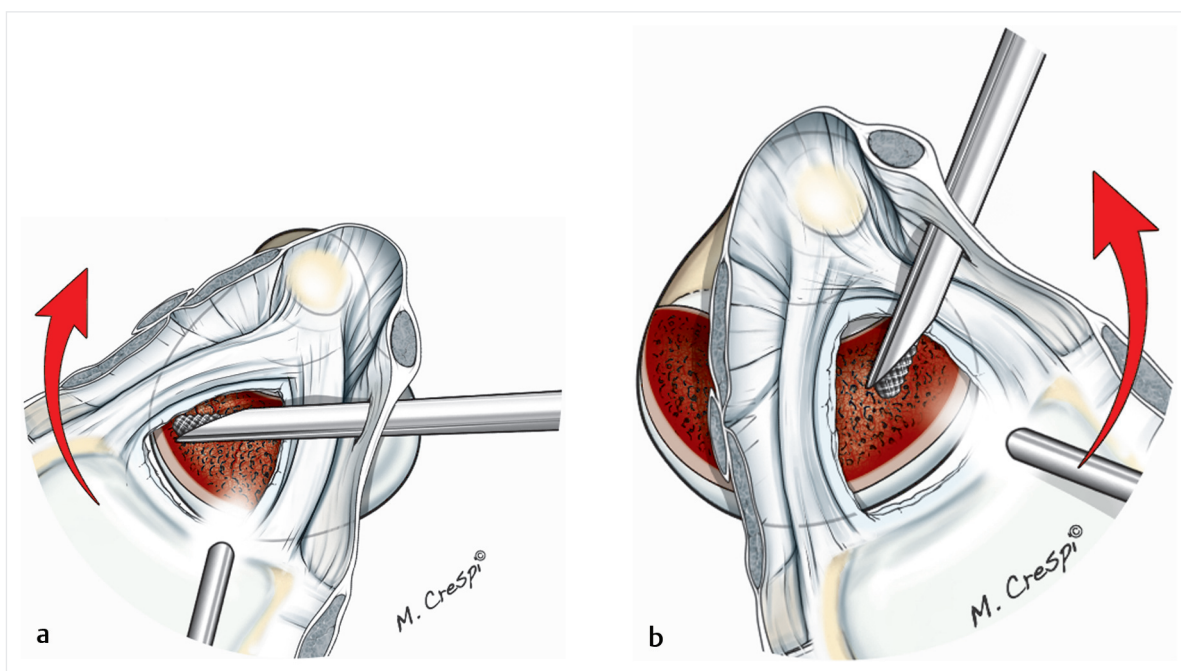


Fig. 12.6a, b

- a** Drawing of the view from above showing continued resection of the ulnar head during wrist pronation. The red arrow shows the pronation movement.
- b** Drawing of the view showing continued resection of the ulnar head during wrist supination. The red arrow shows the supination movement.

resection step, the distal radioulnar joint (DRUJ) must be preserved (Fig. 12.7a–c). At the end of this step, the articular surface has undergone a helicoidally oblique osteotomy. Fluoroscopy can be used to verify the outcome (Fig. 12.8a, b).

Ulnar Head Resection When the Triangular Fibrocartilage Complex Is Intact

In rare cases, mainly in young patients, the TFCC will be intact. A subligament approach can be used to avoid perforating the TFCC when exposing the ulnar head. The scope is placed in the distal radioulnar portal. The shaver is inserted through the direct foveal portal. Resection is carried out as already described, with the assistant pronating and supinating the wrist. It can be useful to reverse

the scope and bur positions to put the finishing touches on the osteotomy (Fig. 12.9a, b).

Closure and Postoperative Care

At the end of the procedure, the small portal incisions are left open under the dressing. Wrist mobilization can start immediately.

Conclusion

Arthroscopic resection of the distal ulna is now the preferred technique for ulnar impaction syndrome in patients where the ulnar variance does not exceed 4 mm. The outcomes are excellent as long as the integrity of the DRUJ is preserved (Fig. 12.10a, b). Postoperative recovery is much simpler, and patients can immediately use their wrist.

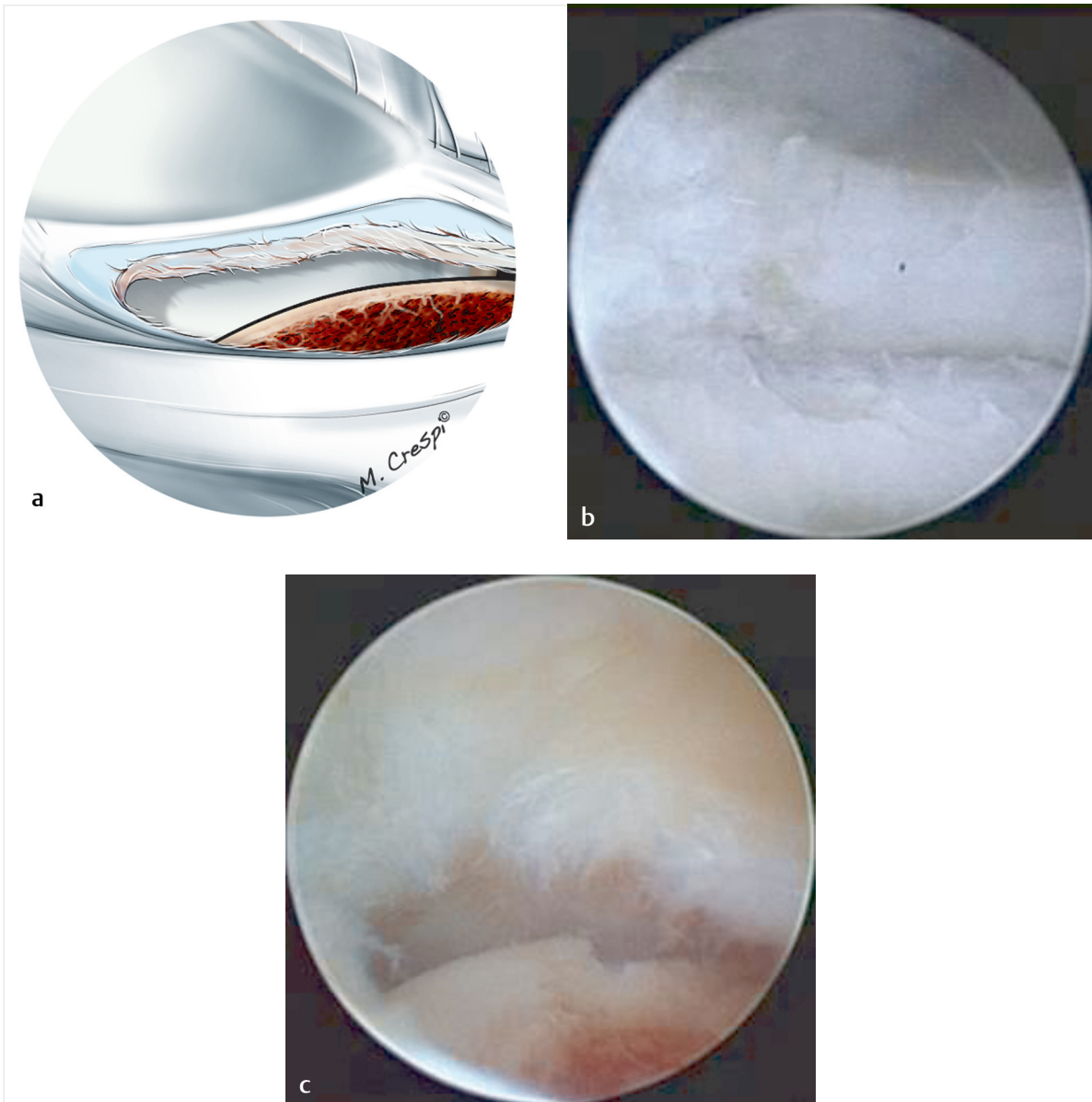


Fig. 12.7a–c

- a** Drawing of the preserved distal radioulnar joint after the ulnar head has been resected.
- b** Arthroscopic view of the intact radioulnar joint after ulnar head resection.
- c** Arthroscopic view of the ulnar head cartilage articulating with the sigmoid fossa of the intact radius.

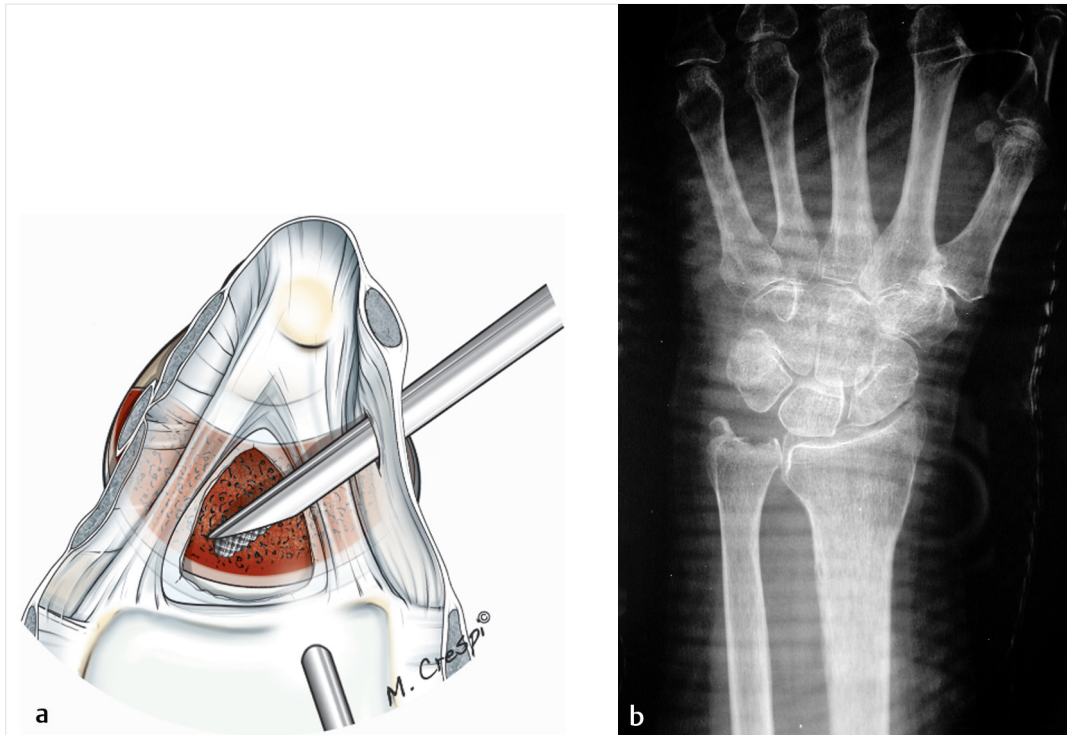


Fig. 12.8a, b

a Drawing of the view from above showing the final appearance of the resected ulnar head. Not level, it is rather oblique and helicoidal.
b Postoperative radiograph showing the degree of ulnar resection and removal of the impingement with preservation of the entire distal radioulnar joint.

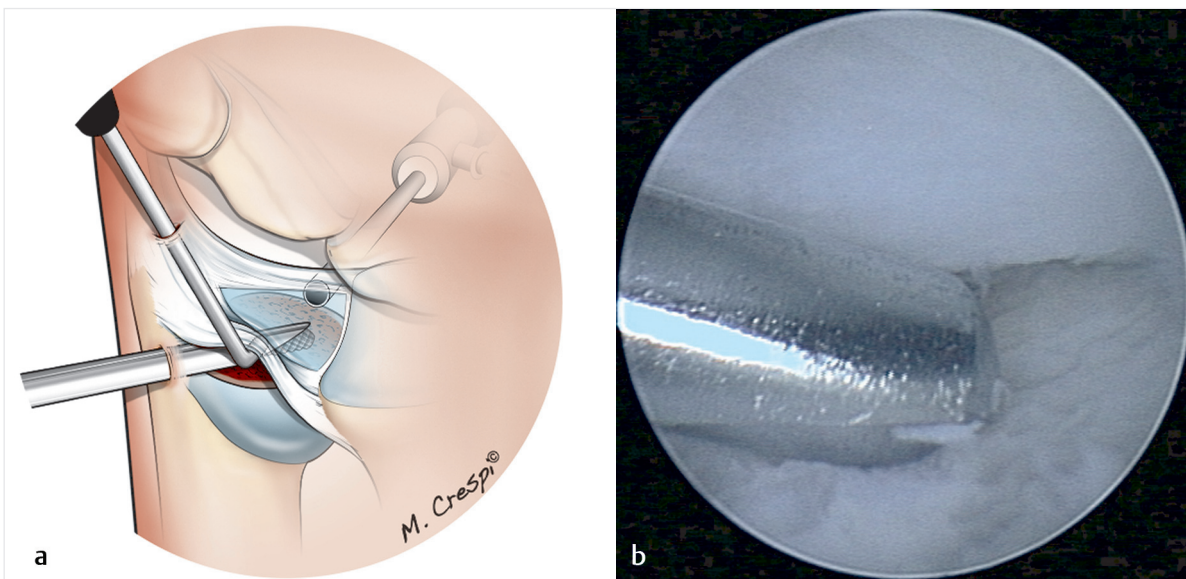


Fig. 12.9a, b

a Drawing of ulnar head resection when the triangular fibrocartilage complex (TFCC) is intact. The scope is placed in the distal radio-ulnar portal, and the shaver is inserted through the direct foveal portal so it lies under the TFCC. The probe (or skin hook) inserted through the 6R portal is used to lift the TFCC.
b Arthroscopic view of the shaver under the TFCC.

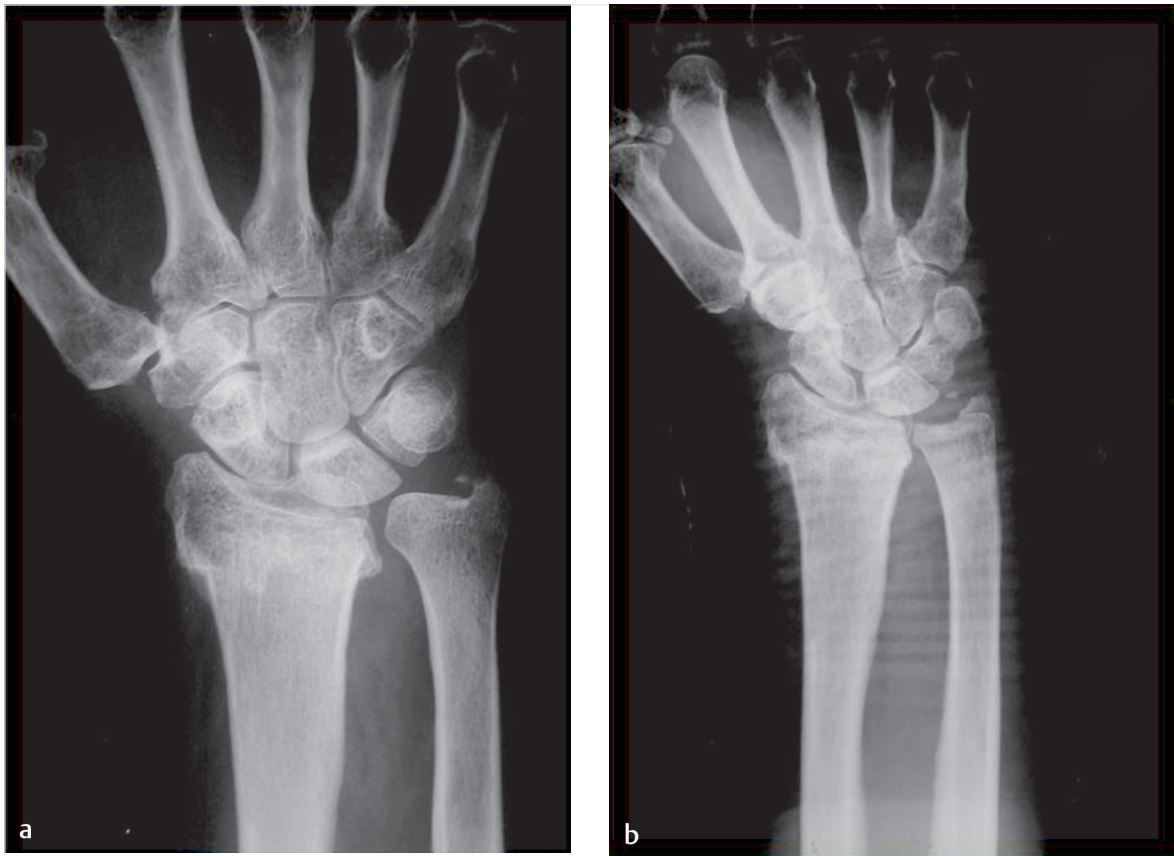

Fig. 12.10a, b

a Radiograph of ulnar impaction syndrome secondary to a radius fracture.

b Radiograph showing the final result after ulnar head resection; the distal radioulnar joint is intact.

