

Anatomy of the Triangular Fibrocartilage Complex:

Chapter 7 Current Concepts

Introduction

The triangular fibrocartilage complex (TFCC) is one of the intrinsic ligaments of the wrist. It is often injured due to a fall on an outstretched hand or in association with distal radius fractures, and central perforations are commonly seen in degenerative processes during aging. It contributes to the stability of the distal radioulnar joint and the ulnocarpal joint. The nomenclature—*triangular fibrocartilage complex*—is apt because it reflects both structure and anatomical shape. Many recent cadaver and arthroscopic studies have elucidated its exact anatomy and function.^{1,2} This knowledge clarifies the biomechanical role of the TFCC and guides the arthroscopic management of TFCC tears.²

Histology

The TFCC is composed of two histologically different types of tissues. The central fibrocartilage disk represents 80% of the area of the TFCC. It is avascular and consists of collagen type 1 fibers, which are oriented according to tensile forces and grouped in bundles, with fusiform chondrocytes in the matrix.³ This central disk attaches to the hyaline cartilage that covers the distal radius⁴ and extends as a meniscus homologue. The peripheral 20% of the disk is vascularized, as are its extensions: the ulnocarpal ligaments (volar), and the sheath of the extensor carpi ulnaris (ECU) (dorsal). These structures are composed of loose vascularized connective tissue, with fibroblasts that secrete proteoglycans and extracellular matrix. They are interspersed in a gelatinous matrix composed of collagen fibers and elastin fibers. The TFCC is inserted on the fovea of the ulna by Sharpey fibers, which are vertically oriented. At the base of the ulnar styloid, the fibers are oriented horizontally. The ECU tendon subsheath is also firmly attached to the dorsal aspect of the fovea by Sharpey fibers.⁵ In contrast, the ulnocarpal ligaments do not have any Sharpey fibers.

Thus the TFCC is composed of a vascularized portion and a nonvascularized portion. Vascularization is supplied from branches of the posterior interosseous artery, the ulnar artery, and the medullary arteries of the head of the ulna at the fovea. This histological difference explains the pathophysiology of TFCC lesions. The central disk and its radial insertion are avascular and cannot heal spontaneously. The peripheral portion of the TFCC is well vascularized and has a good healing potential. Macroscopically it is often difficult to distinguish between the fibrocartilaginous and the ligamentous parts.

Anatomy

The TFCC is located between the ulna and the proximal carpal row (opposite the lunate and the triquetrum). It thus supports the distal radioulnar joint (DRUJ) in its proximal portion. The DRUJ is formed by the articulation between the concave sigmoid notch located on the medial aspect of the distal end of the radius and the articular surface of the ulnar head (Fig. 7.1). The DRUJ is stabilized by dorsal and volar radioulnar ligaments, the TFCC, and the joint capsule.

The TFCC consists of five parts:

1. The fibrocartilaginous disk and the meniscal homologue
2. The ulnocarpal ligaments on the volar aspect (the ulno-lunate and the ulnotriquetral ligaments) (Fig. 7.2)
3. The dorsal and volar radioulnar ligaments (each with a superficial and deep part) (Fig. 7.3a, b)
4. The ulnar collateral ligament
5. The floor of the fibrous fifth and sixth extensor compartments (Fig. 7.4)

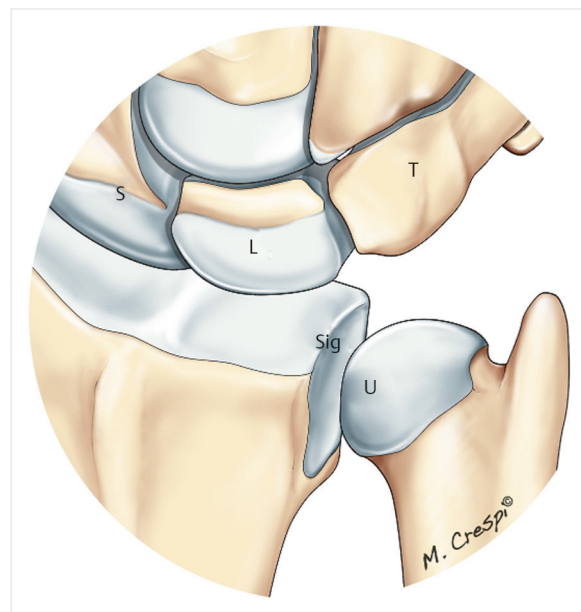


Fig. 7.1 Drawing of the distal radioulnar joint (DRUJ). S, scaphoid; L, lunate; T, triquetrum; Sig, sigmoid notch of radius; U, distal articular surface of the ulnar head.

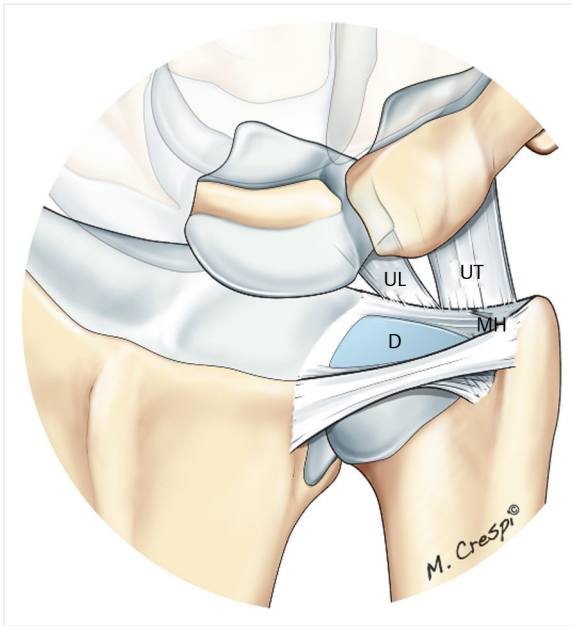


Fig. 7.2 Drawing of the distal portion of the triangular fibrocartilage complex. D, disk; MH, meniscal homologue; UL, ulnolunate ligament; UT, ulnotriquetral ligament.

The central disk is a robust fibrocartilaginous structure extending between the ulna and the radius. The base of the disk is attached to the sigmoid notch of the radius, whereas the apex is attached to the fovea at the base of the ulnar styloid on the head of the ulna. The foveal insertion of the TFCC is not seen during wrist arthroscopy

using the standard radiocarpal portals. This important part of the TFCC is best visualized using the DRUJ portals. These fibers are part of the “iceberg” concept propagated by Atzei and Luchetti.² The central fibrocartilaginous disk continues medially and volarly to merge with the ulnar collateral ligament and the ulnocarpal ligaments, respectively. The ulnocarpal ligaments (the ulnolunate and the ulnotriquetral ligaments) do not insert onto the ulna but are derived from the anterior part of the TFCC, and they connect the carpus (lunate, triquetrum, and capitate³) to the ulna by the palmar portion of the radioulnar ligament at its origin—the fovea.⁶ The radioulnar ligaments (dorsal and volar) arise from the medial aspect of the distal radius. They insert at different points onto the ulna (the deep fibers insert onto the fovea, whereas the superficial fibers insert onto the styloid process).

Palmer and Werner⁷ had a two-dimensional view of the TFCC. However, since the work of Nakamura and colleagues,^{1,4,6} it is interesting to understand the dynamic function and analyze the TFCC in its three-dimensional structure. One can therefore schematically separate the TFCC into three zones: a proximal zone corresponding to the insertion of the triangular foveal ligament, a distal region corresponding to the “hammock,” and an outer area corresponding to the ulnar collateral ligament (Fig. 7.5).

Biomechanics

The TFCC plays an important role in the biomechanics of the carpus and DRUJ.^{4,7} It stabilizes the DRUJ and the ulnocarpal joint. The TFCC allows the transmission and

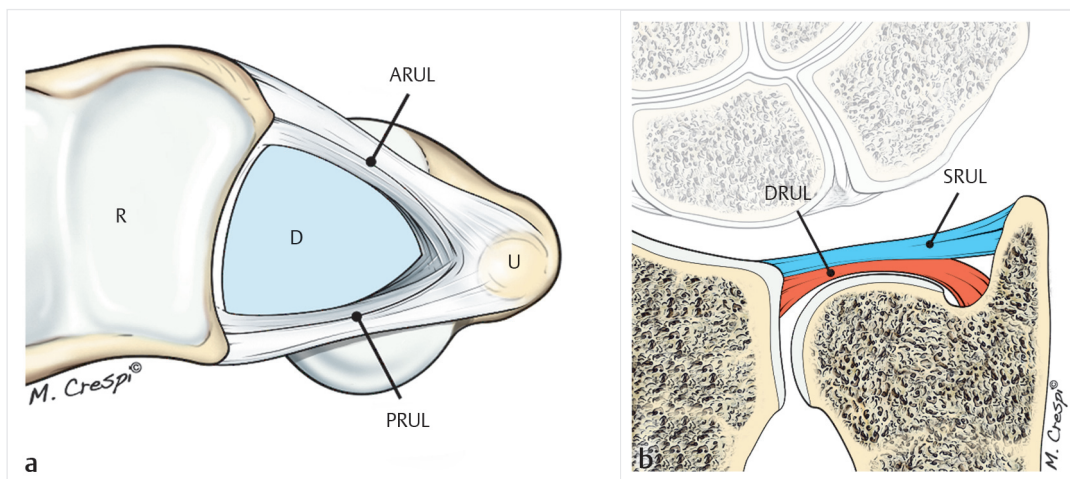


Fig. 7.3 a, b

- a** Drawing of the distal portion of the triangular fibrocartilage complex (TFCC). R, radius; D, disk; U, ulna; ARUL, anterior radioulnar ligament; PRUL, radioulnar ligament.
- b** Drawing showing a portion of the RUL composing the TFCC. DRUL, deep radioulnar ligament; SRUL, superficial radioulnar ligament.

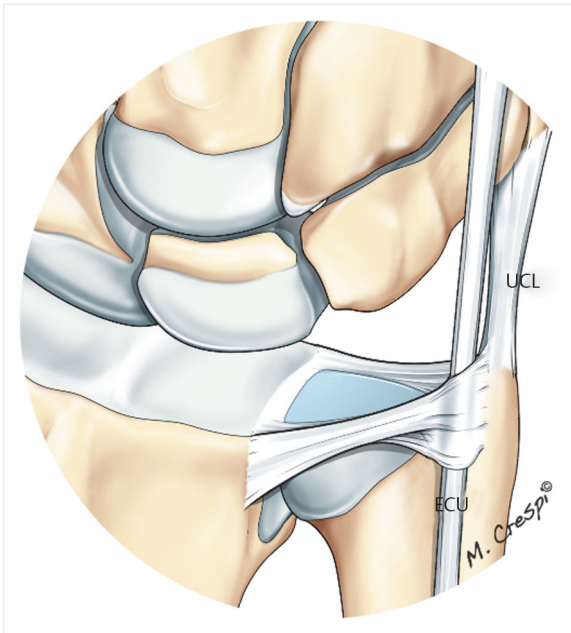


Fig. 7.4 Drawing of the dorsal and medial portion of the triangular fibrocartilage complex. ECU, extensor carpi ulnaris tendon; UCL, ulnar collateral ligament.

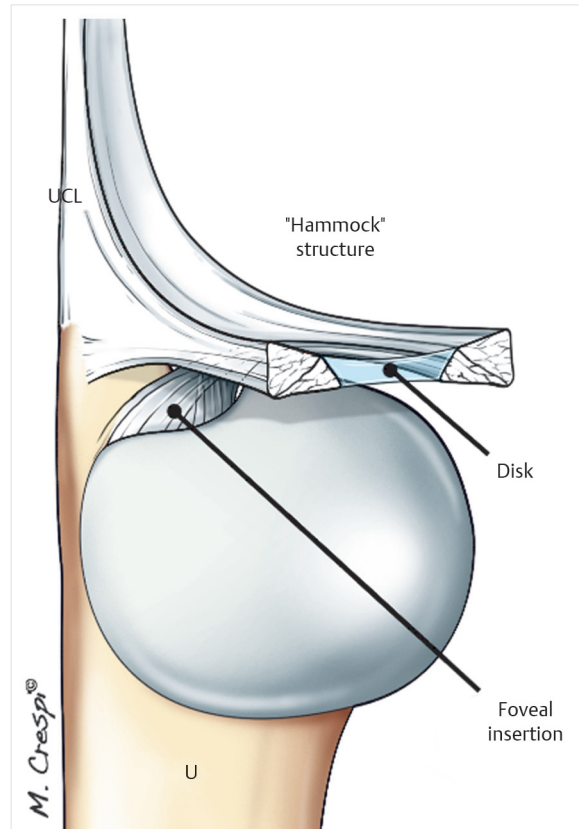


Fig. 7.5 Three-dimensional structure of the triangular fibrocartilage complex by Nakamura⁹ (“hammock” concept). UCL, ulnar collateral ligament; U, ulna.

distribution of forces from the wrist onto the ulna and provides a gliding surface for the carpus during complex movements of the wrist. The central disk is important for the distribution of mechanical stresses on the proximal part of the triquetrum and the lunate. The TFCC and its components differentiate humans from primates and allow 6 degrees of movements at the wrist joint: flexion, extension, supination, pronation, and ulnar and radial deviation.

The proximal part of the TFCC stabilizes the DRUJ, whereas the distal portion, resembling a hammock, supports the ulnar carpus. During pronation and supination the central disk deforms only slightly (**Fig. 7.6**), whereas the triangular ligament twists significantly at its insertion on the fovea of the ulna. The ulnar collateral ligament is also deformed during pronation and supination. The relationship between the radius and the ulna changes with pronosupination: in supination the head of the ulna is relatively volar to the radius, whereas in pronation it is dorsal to the distal radius. In fact, in supination the radius translates dorsally⁶ and causes certain fibers of the TFCC to tighten, namely, the superficial fibers of the volar radioulnar ligament and the deep fibers of the dorsal radioulnar ligament.⁹ In pronation, conversely, the radius translates into the volar position, and the superficial fibers of the dorsal radioulnar ligament and deep fibers of the volar radioulnar ligament are stretched out (**Fig. 7.7**). It is therefore imperative to move the DRUJ through the

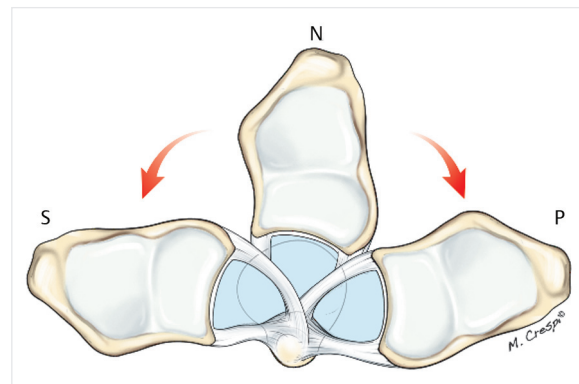


Fig. 7.6 Drawing showing the dynamic changes of length of ARUL and PRUL during movement of pronation-supination. P, pronation; S, supination; N, neutral. Minor changes according to Nakamura.⁹

entire range of pronosupination when exploring the TFCC arthroscopically.

The TFCC plays a key role in the intrinsic stability of the DRUJ. Extrinsic stability is provided by the ECU subsheath, the

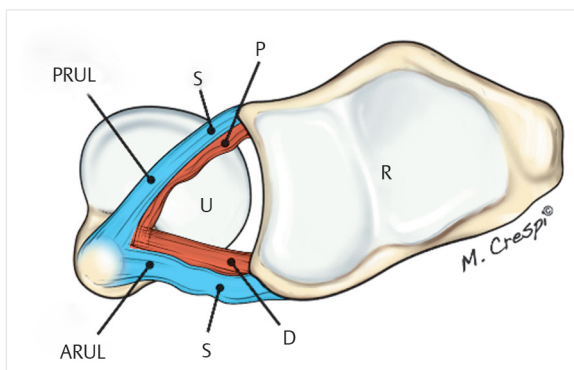


Fig. 7.7 Drawing showing the position of the fibers of radioulnar ligaments in wrist pronation. Note that the superficial fibers of the radioulnar ligament (RUL) are stretched, and posterior root fibers of the PRUL are loose, whereas the reverse is true with the radioulnar ligament. ARUL, anterior radioulnar ligament; PRUL, posterior radioulnar ligament; S, superficial fibers; D, deep fibers; U, ulna; R, radius.

distal fibers of the interosseous membrane, and the pronator quadratus muscle. In extreme movements, the DRUJ capsule prevents dislocation of the joint.

Arthroscopic Examination of TFCC Tears

Three arthroscopic tests are used to check the type of TFCC lesion:

1. The “trampoline sign”: This test is used to assess for overall loss of elasticity of the TFCC. Normally, the TFCC is as taut as a trampoline. A loss of the trampoline effect is seen in complete avulsion injuries of the proximal and distal portions of the TFCC. It may be negative in isolated proximal lesions and equivocal in partial distal lesions (**Fig. 7.8**).
2. The hook sign (of Atzei and Luchetti²): During the hook test a ripple effect can be seen when the ulnar attachment of the TFCC is pushed toward the radius. It is positive in complete tears of the TFCC and negative in other patients. The hook probe is introduced at the foveal region. It then passes under the TFCC. The TFCC is then pulled up by traction applied with the hook probe from under the TFCC. In case of avulsion of its foveal insertion and of the superficial portion, the probe creates a ripple effect on the TFCC. The hook test is then considered positive (**Fig. 7.9a-c**).
3. The “ghost sign” (Fontes) characterizes a “reverse trampoline sign.” When the hook is inserted into the

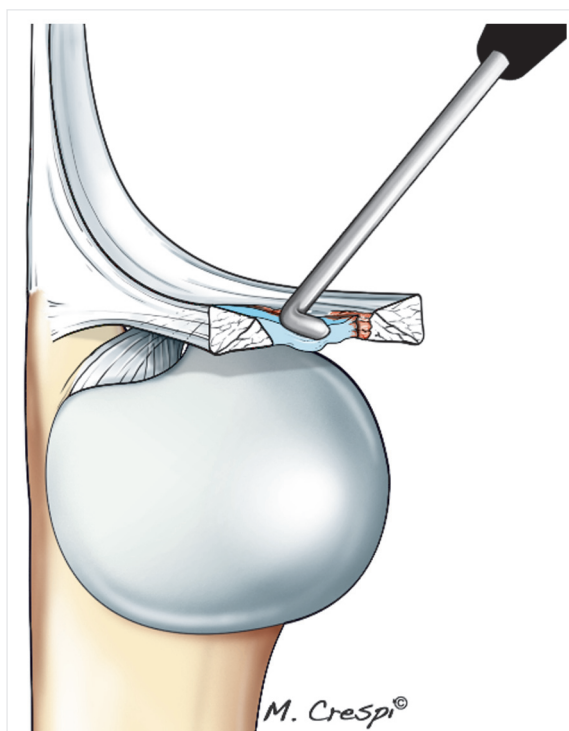


Fig. 7.8 Drawing of the “trampoline sign,” indicating an overall loss of elasticity of the triangular fibrocartilage complex (TFCC). The probe is placed in the 6R portal and will test the resilience of the TFCC.

DRUJ, a “ghost” effect observed on the radiocarpal aspect of the TFCC indicates an avulsion of the deep fibers of the TFCC. Unlike the hook sign, the ghost sign is negative in distal lesions and positive in isolated proximal lesions (**Fig. 7.10**).

Conclusion

Knowledge of the histological differences of the TFCC components, especially with regard to their vascularization, is important for understanding the healing potential of different TFCC lesions. An understanding of the complex anatomy of the TFCC (its three-dimensional structure and insertions) is helpful in identifying lesions that were unknown or little understood before the advent of arthroscopy, especially avulsion of the TFCC at its foveal insertion on the head of the ulna.

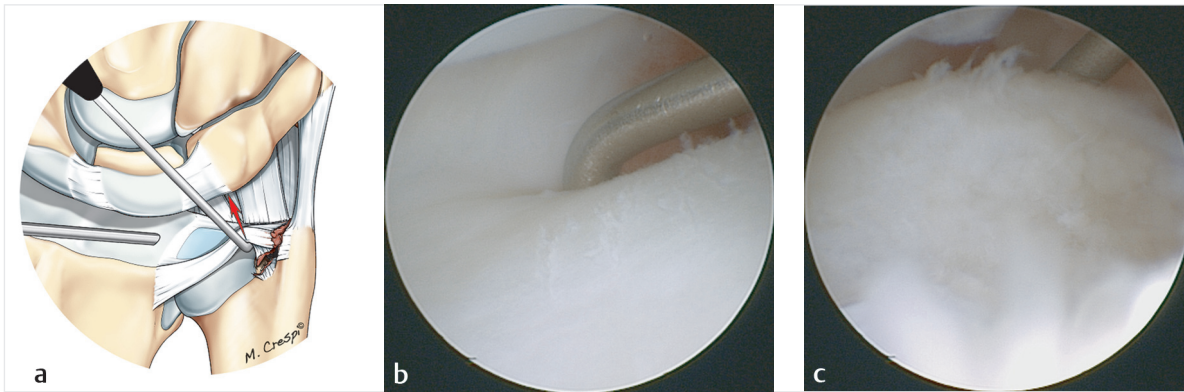


Fig. 7.9a–c

a Drawing of the “hook sign” looking for a wave effect in repelling the ulnar attachment of the triangular complex to the radius. The probe introduced into the 6R portal is positioned at the styloid recess and “pushes” the triangular fibrocartilage complex (TFCC) to the radial side. In the case of a break, a raised ripple effect is visible.

b Arthroscopic view showing the probe positioned at the styloid recess.

c Arthroscopic view showing the creation of the ripple when the probe pushes the TFCC toward the radius.

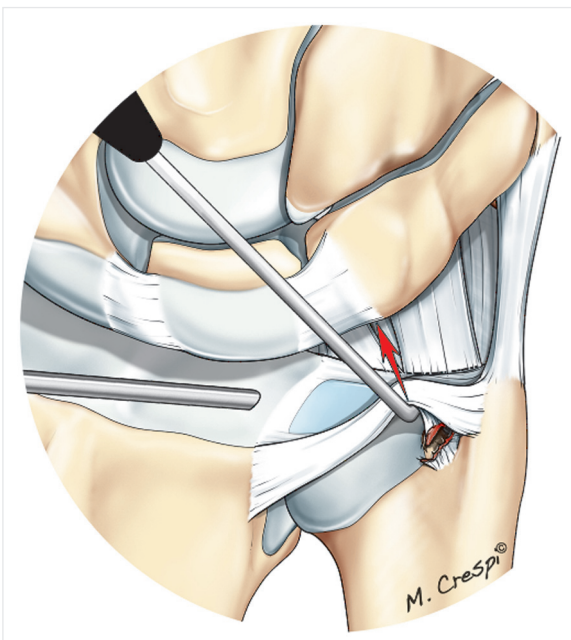


Fig. 7.10 Drawing of the “ghost sign.” Looking for a ghost effect on the foveal side of the triangular fibrocartilage complex (TFCC) by inserting the hook into the RUD and pushing the probe up and down the radius. In the case of an isolated fracture of the foveal insertion of the TFCC, a rising ghost wave can be seen.

References

1. Nakamura T, Yabe Y, Horiuchi Y. Functional anatomy of the triangular fibrocartilage complex. *J Hand Surg Am* 1991a;16(6):1101–1105
2. Atzei A, Luchetti R. Foveal TFCC tear classification and treatment. *Hand Clin* 2011;27(3):263–272
3. Bednar MS, Arnoczky SP, Weiland AJ. The microvasculature of the triangular fibrocartilage complex: its clinical significance. *J Hand Surg Am* 1991a;16(6):1101–1105
4. Nakamura T, Takayama S, Horiuchi Y, Yabe Y. Origins and insertions of the triangular fibrocartilage complex: a histological study. *J Hand Surg [Br]* 2001;26(5):446–454
5. Joshi SS, Joshi SD, Jadhav SD, Athavale SA, Waghmode PS. Triangular fibrocartilage complex (TFCC) of wrist: some anatomico-clinical correlations. *J Anat Soc India* 2007;56:8–13
6. Nakamura T, Makita A. The proximal ligamentous component of the triangular fibrocartilage complex. *J Hand Surg Br* 2000;25(5):479–486
7. Palmer AK, Werner FW. The triangular fibrocartilage complex of the wrist—anatomy and function. *J Hand Surg Am* 1981;6(2):153–162
8. Hagert CG. Distal radius fracture and the distal radioulnar joint—anatomical considerations. *Handchir Mikrochir Plast Chir* 1994;26(1):22–26

